

# Cataract Surgery for Greenhorns



**Thomas A. Oetting, MS, MD**  
University of Iowa  
VAMC Iowa City

*Iowa City Iowa  
November 2012*

## Outline

- 1) **Training Plan**
- 2) **Assessment**
  - a. **Classic Types of Cataract**
  - b. **Evaluation of Patients with cataract**
  - c. **Difficulty Factors**
- 3) **Preoperative**
  - a. **Consent**
  - b. **IOL Selection**
  - c. **Adjusting the Operating Microscope**
- 4) **Anesthesia**
- 5) **Cataract Surgery – Old School**
- 6) **Phacoemulsification Step by Step**
- 7) **Phacoemulsification Machine Primer**
- 8) **Ophthalmic Viscoelastic Devices (OVD)**
- 9) **Capsular Staining**
- 10) **Postoperative Care**
- 11) **Vitreous Prolapse and Anterior Vitrectomy**
- 12) **Conversion to ECCE**
- 13) **Approaching the Unusual Cataract**

## Training Plan -- Cataract

Our training plan sets up Dreyfus stages for the acquisition of the skill of cataract surgery and more specifically phacoemulsification. A **beginner** has some skills in the wet lab and can do parts of cases. An **advanced beginner** can do simple cases with one hand. A **proficient** surgeon can do routine cases with both hands and some complex cases. Residents would not be expected to be an **expert** who could do routine cases with little thought and develop techniques for more complex cases. Each stage has expectations associated with it.

### First year – Beginner

#### Expectations following the first year or at “Beginner Stage”

- know accepted names of all instruments in VA cataract tray
- describe all steps of phacoemulsification cataract surgery
- describe common complications of cataract surgery
- demonstrate ability to fold and insert IOL into capsular bag
- demonstrate ability to prep and drape eye
- demonstrate ability to drive operating microscope
- demonstrate ability to place a single suture
- demonstrate ability to remove OVD
- demonstrate ability to perform Yag capsulotomy
- manage routine cataract patients postoperatively
- describe findings of CME on OCT and FFA
- describe common complications of Yag capsulotomy

#### Resources to develop these skills

Wet Lab fully equipped, dedicated facility at VAMC work in wet lab w/cadaver or pig eyes

<http://medrounds.org/ataract-surgery-greenhorns> or down load to ipad using itunes  
<http://webeye.ophth.uiowa.edu/eyeforum/tutorials/instruments/Phacoemulsification/index.htm>  
<http://facebook.com/ataract.surgery>

ipod with greenhorn series: ICCE, ECCE, prep, RB, AEL, microscope, my first cataract

"Backing in" (doing parts of cases) -- concept developed by Mark Wolken MD

VA rotation – Wednesday. Backing into 3rd year cases to slowly do more of “back” of case  
UIHC Dr Kutzbach -- Monday AM backing into cases

M&M Conf Practice Based Learning every 10 weeks

Phaco Course Madison Wisconsin (UW, UI, MCW residents) lectures ½ day/wet lab ½ day

Expectation	Assessment	Resources
know accepted names of all instruments in VA cataract tray	Demonstrate in OR	Ipod Greenhorns Eyerounds.org

describe all steps of cataract surgery	Oral	Greenhorns
describe common complications of cataract surgery	Oral	Greenhorns
demonstrate ability to fold and insert IOL into capsular bag	Demonstrate in OR	Wet Lab ipod Greenhorns
demonstrate ability to prep and drape eye	Demonstrate in OR	ipod Greenhorns
demonstrate ability to drive operating microscope	Demonstrate in OR	Wet Lab ipod Greenhorns
demonstrate ability to place a single suture	Demonstrate in OR/wet lab	Wet Lab
demonstrate ability to remove OVD	Demonstrate in OR	Wet Lab
demonstrate ability to perform Yag capsulotomy	Demonstrate in clinic	
manage routine cataract patients postoperatively	Demonstrate in clinic	Greenhorns
describe findings of CME on OCT/FFA	Oral	
describe common complications of Yag capsulotomy	Oral	Greenhorns

## Second Year – Advanced Beginner

### Expectations following the second year or at “Advanced Beginner Stage”

- know name of all instruments on all VA eye trays
- consent patient for routine cataract surgery
- perform 5 uncomplicated phaco cases (attending may assist with 2<sup>nd</sup> hand) < 45min
- describe steps to convert to ECCE
- describe technique of anterior vitrectomy
- demonstrate ability to perform IOL Master
- demonstrate ability to place multiple sutures efficiently
- demonstrate ability to use capsular dye

### Resources to develop these skills

Wet Lab fully equipped, dedicated facility at VAMC work in wet lab w/cadaver or pig eyes

<http://medrounds.org/cataract-surgery-greenhorns> or down load to ipad using itunes

<http://eyerounds.org/tutorials/instruments/Phacoemulsification>

<http://facebook.com/cataract.surgery>

Observed Professional Communication Competency Consent feedback on EPIC

OR formative feedback form for portfolio

VA rotation – Wed and Friday AM observe 3<sup>rd</sup> year 1<sup>st</sup> case

VA rotation – Thursday AM – Dr Oetting 1-3 cases Oetting will help with second instrument at first usually with retrobulbar anesthesia. all cases video taped for review

UIHC rotation – Tuesday – Dr Johnson transition to topical anesthesia deliberate practice on capsulorhexis. video formative feedback

M&M Conf Practice Based Learning Competency every 10  
 Phaco Course Madison Wisconsin (UW, UI, MCW residents) advanced lectures ½ day/wet lab ½ day  
 Texts in library: Chang Phaco Chop; Sielbel Phaco Dynamics

Expectation	Assessment	Resources
know name of all instruments on all VA eye trays	Oral	ipod EyeRounds.org
consent patient for routine cataract surgery	Jan Full	ipod
perform 5 uncomplicated phaco cases < 45min	Formative feedback forms	Ipod facebook
describe steps to convert to ECCE	Oral	Greenhorns facebook
describe technique of anterior vitrectomy	Oral	Greenhorns facebook
demonstrate ability to perform IOL Master for AEL	Observe in clinic	Clinic staff
demonstrate ability to place multiple sutures efficiently	Observe in OR	Wet Lab
demonstrate ability to use capsular dye	Observe in OR	Greenhorns facebook

### Third Year -- Proficient

#### Expectations following the third year or at “Proficient Stage”

- understand IOL selection
- consent patient for complex cataract surgery (eg CTR, ICG)
- perform 5 phaco cases with 2 hand < 30min
- demonstrate or deeply understand conversion to ECCE
- demonstrate or deeply understand anterior vitrectomy
- demonstrate or understand sulcus IOL placement
- understand phacoemulsification machine settings
- understand OVD selection
- demonstrate ability to use iris hooks

#### Exceptional samples of behavior rarely seen during third year “Expert Stage”

- demonstrate ability to use McCannell suture
- demonstrate ability to use CTR
- demonstrate ability to do very efficient cataract surgery < 15 minutes
- demonstrate ability to use phaco chop techniques
- staff first years during portions of cataract surgery

#### Resources to develop these skills

Wet Lab fully equipped, dedicated facility at VAMC work in wet lab w/cadaver or pig eyes

<http://medrounds.org/cataract-surgery-greenhorns> or down load to ipad using itunes  
<http://webeye.ophth.uiowa.edu/eyeforum/tutorials/instruments/Phacoemulsification/index.htm>  
<http://facebook.com/cataract.surgery> eg: transition to phaco chop, phaco chop with Ozil,

OR learning with formative feedback form for portfolio

VA rotation – Wednesday AM Oetting,, 4-10 cases, develop ability to use second instrument, develop skills to do topical cases, transition to chopping technique

UIHC Comprehensive rotation Thursday Kitzmann 2-5 cases emphasis on chopping and efficiency

UIHC Comprehensive rotation Friday Oetting 2-5 cases emphasis on complex cases and efficiency

M&M Conf Practice Based Learning Competency lead conference every 10 weeks open discussion of complicated cases at UIHC and VAMC UI during rounds

Phaco Course Madison Wisconsin (UW, UI, MCW residents) advanced lectures ½ day/wet lab ½ day

Texts in library: Chang Phaco Chop; Sielbel Phaco Dynamics, Chang Curbside

<b>Expectation</b>	<b>Assessment</b>	<b>Resources</b>
understand IOL selection	Oral	Greenhorns
consent patient for complex cataract surgery (eg CTR, ICG)	Oral	
perform 5 phaco cases with 2 hand < 30min	Formative Feedback Form	
demonstrate or deeply understand conversion to ECCE	Oral	Greenhorns Facebook
demonstrate or deeply understand anterior vitrectomy	Oral	Greenhorns facebook
demonstrate or understand sulcus IOL placement	Oral	Greenhorns facebook
understand phacoemulsification machine settings	Oral	Greenhorns facebook
understand OVD selection	Oral	Greenhorns facebook
demonstrate ability to use iris hooks	Observe in OR	Greenhorns facebook

## Summary of Cataract Training Plan

Dreyfus Stege	Level	Expected Samples of Behavior For this level	Typical rotation at this level	% grads at this level	Resources to Grow beyond this level
<b>Novice</b>	Starting	Desire to learn	n/a		Books video observe
	assistant surgeon	demonstrate sterile technique know all instruments in tray know all steps of cataract surgery demonstrate prep and drape demonstrate IOL fold demonstrate RB injection	VA 1 <sup>st</sup> yr		Books wet lab video observe
<b>Beginner</b>	wet lab surgeon	demonstrate microscope use pig/cadaver eye with faculty	VA 1 <sup>st</sup> yr		wet lab video back into cases
	neophyte surgeon	demonstrate suture technique demonstrate IOL placement demonstrate use of I/A device	VA 1 <sup>st</sup> yr		wet lab video back into cases
<b>Advanced Beginner</b>	Basic cataract surgeon	demonstrate 5 cases < 45 min know steps to convert to ECCE know steps for vitreous loss demonstrate use of capsule dye demonstrate effective consent	VA 2 <sup>nd</sup> yr	100%	wet lab video develop non-dominant hand
	assistant topical surgeon	demonstrate capsulorhexis during topical case assist efficient cataract surgeon	UI 2 <sup>nd</sup> yr	100%	video deliberate practice
<b>Proficient</b>	two handed surgeon advanced surgeon	demonstrate 5 cases < 30 min using both hands demonstrate topical cases demonstrate the use of small pupil techniques demonstrate the use of CTR demonstrate chopping techniques demonstrate IOL suturing techniques	VA 3 <sup>rd</sup> yr  VA 3 <sup>rd</sup> yr DM 3 <sup>rd</sup> yr UI 3 <sup>rd</sup> yr	95%  50%	video  video
<b>Expert</b>	efficient innovative surgeon	demonstrate 5 cases < 15 min develop new techniques	graduates	rare	video practice

## Classic Types of Cataract

Type	Age of Onset	Symptoms
Nuclear	60-70	Myopic shift Blurred vision Loss of blue/yellow color perception
Posterior Subcapsular	40-60	Glare Diminished reading Monocular diplopia
Cortical	40-60	Glare Monocular diplopia

### Nuclear cataract

#### Epidemiology/Risk Factors

Age

Riboflavin, Vit C, Vit E and carotene may decrease risk of nuclear sclerosis

Cigarette smoking increase the risk of nuclear sclerosis

#### Symptoms/History

Gradual progressive loss of vision

Second sight -- development of myopia due to increased lenticular refractive index

Monocular diplopia

Decreased color discrimination especially blue

#### Clinical features

Central yellow to brown discoloration of the lens

Myopic shift – increased AP diameter better converging lens

Bilateral

Decreased penetration of cobalt blue slit beam through lens

### Posterior Sub-Capsular Plaque (PSCP)

#### Epidemiology/Risk Factors

Younger patients than with nuclear or cortical cataracts

Diabetes mellitus

Radiation

Corticosteroids

Uveitis including RP

Smoking

#### Symptoms/history

progressive loss of vision, sometimes rapid

Glare, halos

Monocular diplopia

#### Clinical features

Axial opacity of the posterior cortical material

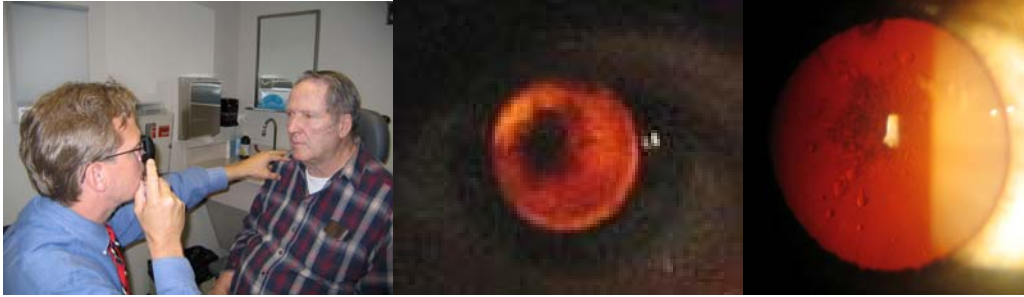
initially an iridescent sheen appears in the posterior cortex

followed by granular and plaque like opacities

Can be confused with posterior polar cataract and mittendorf dot



Can see with direct but best viewed with red reflex through slit lamp



Using direct to see PSCP

view through direct

view through slit lamp

## Cortical Cataract

### Epidemiology/Risk Factors

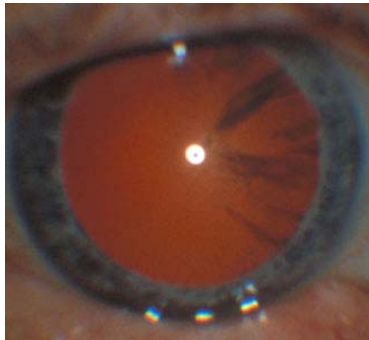
- Younger patients than with nuclear cataracts
- Diabetes mellitus
- Sunlight
- Trauma
- Smoking

### Symptoms/history

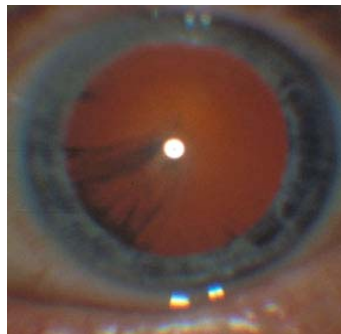
- progressive loss of vision, sometimes rapid
- Glare, halos
- Monocular diplopia

### Clinical features

- opacity of the cortical fibres from posterior to central
- sometimes wedge shaped forming cortical spokes
- can progress to intumescent or hypermature cataract
- usually medial and inferior from UV exposure



right eye



left eye

# Evaluation of patients with cataract

## Ask yourself?

- Is the cataract causing the visual decline?
- Is the cataract secondary to a systemic or ocular condition?
- Could the eye/patient survive cataract surgery if indicated?

## Symptoms of a cataract

- Visual acuity usually a gradual decline over years  
w/post sub-capsular cataract (PSCC) VA can decline over days  
Often near VA decline is greater than far VA decline in PSCC
- Glare night driving problems, halos, especially with PSCC and cortical
- Myopic shift "second sight", especially in nuclear sclerotic cataract
- Diplopia monocular, especially in PSCC and cortical

## Indications for cataract surgery

- Functional, functional, functional.
- Document difficult with reading, driving, glare, recognizing faces, diplopia
- Must document functional decline (in Iowa with form w/patient's signature)
- Best corrected Visual Acuity  $\leq 20/50$  at far or near usually acceptable to insurance
- Best corrected Visual Acuity  $> 20/40$  documentation of disability even more important
- Uncommon indications:
  - lens induced disease, eg. glaucoma
  - medical need to visualize the fundus, eg. diabetes, AMD

## General Issues

- Can your patient lay flat for 30-60 minutes
  - worry with back pain, COPD, CHF
  - could their family MD help optimize their breathing or pain?
- Can your patient lay still
  - Worry with young males, tremor, claustrophobia
  - Consider general anesthesia
  - jiggly spectrum: young men worst  $>$  young women  $>$  old women  $>$  old men least jiggly (yes i am making wild generalizations -- so what!)
- Look at medicine list
  - Coumadin, Plavix, or ASA and if so can they/should they stop? (lots of evidence that it is not necessary to stop. esp aspirin and coumadin. plavix is more scary)
  - Flomax (and other alpha antagonists for BPH)– associated with Intraoperative floppy iris syndrome IFIS consider iris retractor or Maluygin ring. stopping doesnt help though
  - Chronic Steroid Use – usually no need for stress steroid unless general anesthesia
- Latex (pretty much assumed now) and drug allergies
- Can your patient tolerate their post operative care
  - Do they need help putting in their drops
  - Monocular patients may need significant post op help (eg admission) if patched p op
  - sleep apnea patients may have trouble post op if sedated

## Past Ocular History

See section on cataract in special circumstances

h/o glaucoma, steroid response – risk factors for post op pressure spike

h/o RD, tears, lattice, high myopia – risk factors for RD

h/o DM, uveitis, CME in other eye, ERM – risk factors for CME in this eye

h/o DME, CME, ERM, AMD avoid multifocal

## Pre-Operative Exam

Manifest Refraction in both eyes

- Fellow eye refraction may be needed to help with IOL power selection
- Does VA with best correction decline with glare testing -- room lights on and trans-illuminator 45 degrees off axis through phoropter with best refraction
- When vision is poor – document no improvement with +/- 3 diopters

Pupils

- RAPD – as always critical – especially if patient's vision remains poor after surgery
- Dilated pupil Size – useful when selecting among surgeons (see difficulty factors)

CVF -- LP in all four quadrants in dense cataracts (instead of echo)

Keratometer readings of both eyes

- do prior to other K manipulations if possible
- consider on axis surgery
- consider Toric IOL

Topography

- especially when considering Toric IOL
- look for keratoconus and irregular astigmatism

External Exam

- abnormal tear function, lid malposition/exposure, blepharitis/spasm
- Prominent brow/deep socket think temporal and retrobulbar block or schedule for next resident

Slit Lamp Exam

- Cornea – guttata, PPMD, MDF; exposure problems
- lens hardness, phacodonesis, PXF, r/o posterior polar, phacodonesis

Gonioscopy

- important if you may need to place an AC lens, esp with:
- h/o uveitis (possible anterior synechiae)
- h/o DM (may have neovascularization of iris)
- h/o weak zonules (more like to have AC IOL placement)

Dilated Fundus Exam

- not mandatory if you or trusted colleague have looked back recently

- Dilation the day before will inhibit dilation the day of surgery (not huge deal)
- does the poor view match the poor vision
- look carefully at pts with AMD, DM, and ERM, consider pre-op OCT
- document normal macula, ON, PVD if present

Special Tests:

- potential acuity meter – projects an eye chart around lens—rarely helpful
- pin hole with near card and bright light -- good performance predicts good post op VA
- Dense lens no view -- consider B scan echography (can skip with no RAPD and Light projection in all four quadrants)
- Specular microscopy for endo cell count rarely needed eg. FDA Studies, Fuchs'
- Consider pachymetry in patients with corneal edema eg Fuchs'

## Difficulty Factors

### Why assess the difficulty factors preoperatively?

- Which surgeon should do case (eg. Attending vs. 1<sup>st</sup> year resident)
- Estimate length of case
- Determine need for additional supplies/equipment
- Determine the type of anesthesia

### Difficulty Factors (in decreasing order of importance):

- Zonular Laxity (PXF, h/o trauma, marfan's ...)
- Small pupil consider why? PXF, DM s/p laser, CPS, alpha blocker (eg. tamsulosin)
- Cannot lay flat for very long, eg. COPD, claustrophobia, tremor, severe obesity
- Poor red reflex white/black cataract making CCC difficult
- Big brow limiting superior access
- Narrow angle limiting AC space
- Predisposition to corneal decompensation: e.g. guttata, PPMD, hard nucleus
- Past surgery such as existing trab or past PPVx
- Predisposition to exposure: eg: botox, past lid trauma, DM
- Anticoagulants e.g., coumadin, ASA
- Monocular

Factor	Surgeon	Time	Equipment/Anesth.
Zonular Laxity	> 100 cases	Double	Iris or capsule retractors to hold capsule Capsular Ring (CTR) Ready for glued or sutured IOL or sutured (cionni) CTR, CTS Ready for ICCE, eg cryo Consider RB
Small Pupil	> 50 cases	Add 50%	Stretch Pupil (avoid w/ Flomax) Consider Maluygin ring Consider Iris retractors Consider RB
Alpha blocker Tamsulosin (IFIS risk)	> 50 cases	Add 50%	Consider Maluygin ring (use smallest ring you can) Consider Iris retractors diamond (one hook under main incision) Consider single iris retractor Intracameral epi/lidocaine Consider RB
Poor Red Reflex	> 20 cases	Add 50%	Trypan Blue (or ICG) Consider RB
Big Brow	> 20 cases	Add 25%	Consider RB to prolapse anterior Operate temporal Consider sup/inf. bridal sutures
Narrow Angle	> 50 cases	Add 25%	Consider smaller phaco tip Beware of IFIS

			Consider iris hooks diamond configuration Consider BSS+ (w/glutathione) Arshinoff shell w/OVD
Predisposition K decomp	> 50 cases	0%	Consider BSS+ (w/ glutathione) Phaco chop Arshinoff shell w/OVD Consider ECCE , MSICS
Existing Trab	> 20 cases	0%	Avoid Fixation ring Avoid Conj manipulation Malyugin w/small pupil Suture wound following surgery
Past PPVx	> 20 cases	0%	Topical w/long eye to avoid RB Possible CTR Careful during I/A
Cannot Lay flat	> 100 cases	0%	MAC Consider general
Anticoag.	> 20 cases	0%	Topical to avoid injection risk If needed sub tenon's infusion Plavix is most scary
Monocular	> 100 cases	0%	Topical for faster rehabilitation Try to forget about it

## US Medicare Coding Issues

**66984** -- typical code for cataract surgery

**66982** -- complex cataract surgery

surgeon fee 40% more than 66984. facility fee is the same  
indications:

- small pupil -- used Malyugin ring, hooks, or stretched pupil with device like Beehler
- weak zonules -- used Capsular Tension Ring (CTR), CTS
- white cataract -- used Trypan Blue stain
- pediatric cataract -- especially with risk of amblyopia

see these guidelines: <http://www.corcoranccg.com/GetFile.aspx?FileID=d120a671-025c-404e-a68a-72411d20221b>

# Consent

## Most important part of pre-operative visit

5 essential parts of a consent

identify yourself

describe all options – cataract surgery or hold off on cataract surgery

describe the procedure

describe potential risks – 1/100 chance vision will be worse after surgery

describe potential benefit – 9/10 chance vision will be normal with glasses following surgery

Talk your patient through the procedure briefly

we replace your cloudy natural lens with a clear artificial lens

use the words: injection(w/RB), cut, and possible stitches in your discussion

no we don't use the laser (much confusion about Yag for secondary cataract will be femto)

we may patch your eye overnight following the surgery

we will prescribe new glasses when the eye is stable – 2-4 weeks post op

mention co-morbidity such as AMD or glaucoma

Benefits:

95 % better than 20/40

96 % better vision than pre-op

I lower these percents with increasing retinal or optic nerve disease

Risks:

1% vision worse than pre-op

death (<1:100,000)

loss of eye (<1:10,000)

irregular pupil (1:100)

after cataract (1:20 requiring laser in 2 years depends on the IOL)

Document

Functional visual disability, give examples

Complete consent form legibly

In patients chart write something like:

*"I discussed the risks and benefits of cataract surgery with Mr. Jones and his son in terms they seemed to understand. Mr. Jones expressed to me that he understood the small but real risk of surgery, including loss of vision as outlined in the consent form, and he decided to have surgery"*

# Selecting the Intraocular lens (IOL)

## Brief History of the IOL

- Harold Ridley placed first lens in 1949, a huge PMMA IOL (about the size of the crystalline lens)
- 1950s rigid anterior chamber (AC) IOLs were used with ECCE and ICCE
  - bullous keratopathy was common
  - chronic inflammation led to CME and glaucoma
- Later iris fixation lenses were used to avoid contact with the angle
  - Some IOLs would suture onto the iris; others would clip on like Artisan today
  - These lenses would frequently dislocate
- Closed loop flexible anterior chamber (AC) lens were next
  - kept PK surgeons in business
  - caused UGH syndrome (Ellingson syndrome)
- Foldable IOL's came in the 90's and allowed smaller incisions
- Multifocal and toric IOL's came more recently
- Rare and weird names for IOL: pseudophakos, lenticulus

## Today

- Modern open loop flexible AC IOLs are a great success
- The development of viscoelastics (OVDs) allows safe placement
  - Posterior chamber lenses are most commonly used today
  - 3 basic materials – PMMA, acrylic, silicone
  - PMMA is the time tested material but requires a large incision
  - Use the largest optic that can fit incision eg 6.5 or 7 for ECCE
  - Most surgeons use foldable acrylic or silicon lens to allow small incision
- Accomodating IOL (crystal lens) approved by the FDA; better ones coming
- Multifocal (restore, rezoom, array) and toric lenses (staar, alcon) are available

## IOL material considerations

Lens material	Advantages	Disadvantages
PMMA	Time tested Cheapest Little inflammation Less dysphotopsia	Wound size > = optic diameter
Acrylic	Injectable Least inflammation	Cost Dysphotopsia
Silicone	Cost Injectable Less dysphotopsia	More inflammation Silicon oil (for RD repair) adheres to IOL and becomes opaque

## IOL design considerations

Lens design	Examples	Advantages	Disadvantages
Single piece Acrylic	SA 60 SN WF	Smaller incision Easy to insert	Not good in sulcus – haptics too thick



		Stable in bag for toric	
Plate Haptic	Starr	Smallest Incision Easy to insert	Not good in sulcus Be careful with YAG cap -- can fall posterior
3 piece	MA 60 SI 40 AR 40	OK for sulcus	Larger Incision Take care w/ haptics when inserting
Square edge	SA 60 SNWF	Less PCO	More dysphotopsia
Round edge	SI 40	Less dysphotopsia	More PCO

## Four things you need to know to calculate correct IOL power:

### 1) Desired postoperative SE

- Mild myopia like -0.50 to -1.00 is a reasonable plan. Why?
  - Myopia is better than hyperopia if your calculations are off
  - -1.00 gets you about 20/40 at far and you can see well at mid distance
  - A spectacle overcorrection of -1.00 will eliminate induced IOL mag.
- Go for the plano gold OU (reading glasses at near or multifocal)
- Go for monovision
  - minor monovision one eye plano one about -1.00 or so (common with crystal lens -- maybe because it doesn't really work that well)
  - standard monovision one eye plano one about -2.00 or so
  - dominant eye usually set for far
- Match the other spectacle eye as anisometropia > 3.0 is not well tolerated

### 2) Axial eye length (AEL)

- Contact probe ultrasound AEL device
  - Contact probe on eye measures distance to fovea
  - Pushing on the eye w/probe creates error of AEL too short – myopic surprise!
  - Re-measure when AEL difference between eyes >0.3mm
  - Re-measure when AEL <22 or >25
- Laser Interferometry (IOL master, Lenstar)
  - Best technique: quick, little error, clean
  - Less dependant on technician for accuracy
  - Fails in dense NS or even mild PSCP
- Immersion Ultrasound
  - Gold standard when in doubt
  - Cylinder placed on eye, filled with fluid, and probe immersed in fluid but the probe does not contact the eye
  - Some technician skill required but not prone to error from pushing on eye
  - Do immersion whenever patient gets B scan for a dense cataract

### 3) The power of the cornea

- Keratometric measurement of both eyes -- should be about the same
  - Autorefractor
  - IOL Master measures K's for you

- Keratometer
- Corneal topography (especially with Toric or multifocal IOL)
- Difficult when patient has had refractive surgery – long story. Pls see amazing web site by Warren Hill: <http://www.doctor-hill.com/iol-main/keratorefractive.htm>

#### 4) The post operative position of the IOL (effective lens position)

- The more anterior the IOL the less power the IOL needs
  - eg IOL placed in the sulcus needs less power
  - AC depth is a factor in some IOL formula (eg Holliday 2)
- Goal is to place a posterior chamber (PC) lens
  - These can end up in the bag (best) or sulcus (anterior to ant. capsule)
  - Placement of IOL measured for bag in the sulcus results in myopic surprise
    - decrease power by 0.5 to 1 diopter (shorter eye larger shift)
    - If primary lens is a single piece acrylic (eg SNWF) have 3 piece available for sulcus
    - see <http://www.doctor-hill.com/iol-main/bag-sulcus.htm>
- Always plan to have available anterior chamber (AC) lenses
  - These are placed anterior to the iris w/haptics that settle into the angle
  - These are used when the capsule is lost and cannot hold an IOL
  - When too small they can tilt and when too large they can hurt
  - Place peripheral iridotomy before AC IOL to prevent iris bombe

#### Estimating the IOL power for emmetropia:

Formulas started with a theoretical model by Fyodorov, Collenbrander et al, 1970s

Based on geometric optics

$$\text{Power} = N/(\text{AEL}-\text{ACD}) - N/(\text{N}/\text{K}-\text{ACD})$$

where: Power is the expected power of IOL for emmetropia post op

N is the aqueous and vitreous refractive index

ACD is the post operative AC depth of the IOL

AEL is the axial eye length as measured via an ultrasound device

K is average of the two keratometric axes

But you don't know ACD or post operative depth of the IOL pre op!

1) SRK  $\text{Power} = \text{A-constant} - 2.5 (\text{AEL}) - 0.9 (\text{Ave-K})$

**SRK** -- Classic regression formula

developed in 1980 by **S**anders, **R**etzlaff, and **K**raff

where: A-constant is a parameter of the IOL's effective position

eg. PC lens -- Alcon SN60WF A constant of 118.7

AC lens -- Alcon MTA A constant of 115.3

**note** an error of **x** in axial eye length results in an error of **2.5x** in IOL power

SRK falls apart in predictive value with eyes w/AEL <22 and > 24.5

common board question so just know it!

2) Modern regression algorithms are more accurate

SRK/T is best for high myopes

Shorter eyes are tricky for regression formulae

- some short eyes are proportional and regression works

- some short eyes are egg shaped with standard sized AC but short regression fails
- formulae like the Holliday 2 uses AC depth or white to white to better predict the effective lens position in short eyes
- see Dr Hill <http://www.doctor-hill.com/iol-main/formulas.htm>

### Selecting the IOL power for your patient

The SRK computes the lens power for emmetropia; but, you may have a different goal

The U/S or IOL Master produces a table with IOL power mapped to desired post op. SE

- Roughly a change in IOL power of 1.5 produces a change of 1.0 in glasses  
eg. Formula gives 19 diopters for emmetropia, about 20.5 will give -1.00 SE p/o.
- If your estimated IOL power is unusual you are probably wrong
- Double check your calculations
- Trust what happened w/the other eye's IOL if applicable
- If the eye seems too short ask yourself was the patient hyperopic as a young person (eg in the big war before the myopic shift from the cataract)

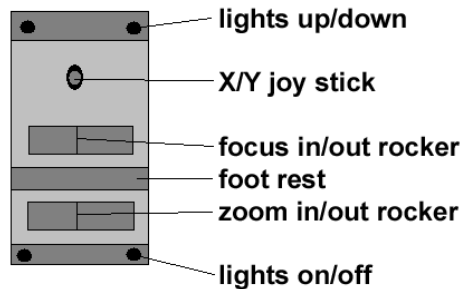
Estimate the power for both the AC and the PC lens compare several formulas

Then if convinced that the calculations are right, make sure that all potentially needed IOL powers are available in the OR

- You will need a posterior chamber lens for the bag (single piece or 3 piece)
- You will need a 3 piece IOL for the sulcus
  - The more anterior sulcus lens will need 0.5-1.0 less diopters of power than it would if placed in the bag
  - Cannot use single piece acrylic (Alcon SA60 or SNWF) in sulcus
- You will need an AC IOL
  - Typical AC lenses come in 3 diameters: 12.5, 13.0, and 13.5 mm.
  - Sized at surgery by adding 1 mm to the "white to white" limbal diameter

# Operating Microscope Basics

Learn how to use your foot pedal and practice before your first case



typical Zeiss foot pedal

Ask yourself: "where will I be sitting?"

Position	Advantages	Disadvantages
Superior	If surgery causes iris trauma lid covers iris If surgery requires lots of sutures (eg ECCE) lid covers sutures Easy to place legs (don't have to go under head) May allow incision on axis	Brow can get in the way Bleb can get in the way
Temporal	Avoid brow Avoid bleb	Sometimes hard to get legs under table Iris trauma can cause glare May not allow incision on axis

## Proper Sequence to adjust Equipment to your body

1. Place retrobulbar block first (give it time to work while setting up scope)
2. Put assistant's eyepiece and camera on proper side of microscope
3. Push center focus and center XY position buttons on microscope (may be same button)
4. Adjust your ocular inter-pupillary distance and zero both objectives
5. Lower surgeons chair
6. Raise bed height to just allow both feet under bed onto both pedals
  - a. Dominant foot – phaco pedal (most people)
  - b. Non dominant foot microscope footswitch (most people)
  - c. Take off shoes (wear white Nike crew length socks -- yes women too)
7. Manually move entire microscope (not with footswitch) so that you are in focus
8. Raise surgeon chair height enough to allow surgeon to see comfortably into oculars
9. Prep and Drape

## Anesthesia

Method	Action	Advantages	Disadvantages
Retrobulbar Block	Akinesia Anesthesia Mydriasis Proptosis Decreases photosensitivity	Great for starting surgeons Proptosis Makes case easy	Risk of globe perforation Risk of Optic nerve injury Risk of muscle damage Risk of retrobulbar hemorrhage Patch post op Conjunctival Chemosis
Subtenon's Block	Anesthesia +/-Mydriasis +/-Akinesia Decreases photosensitivity	No risk of globe perforation Little risk of muscle damage No risk of optic nerve injury Easy to do after placing drape	Conjunctival Chemosis Red conjunctiva Post operative discomfort Patch post op
Peribulbar Block	Anesthesia +/-Mydriasis +/-Akinesia +/-Decrease in photosensitivity	No risk of Optic Nerve injury Little risk of globe perforation	Hard to get to a good block Conjunctival Chemosis Patch post op
Topical intracameral	Anesthesia Mydriasis	Quick Rehab – no patch No risk of orbital injury	Case is harder Epithelial toxicity – coat w/OVD
Topical	Anesthesia	Quick Rehab – no patch No risk of orbital injury	Case is harder Epithelial toxicity – coat w/OVD

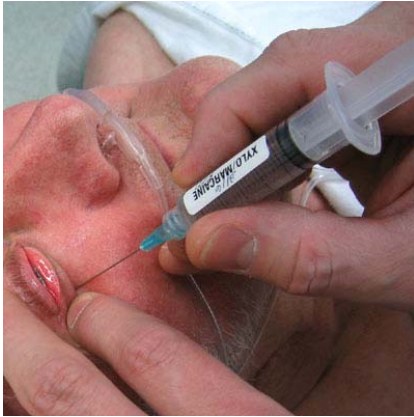### Retro Bulbar Procedure

- Pros:**
- Great for long cases (>45 minutes)
  - Great for inexperienced surgeon (get akinesia, proptosis)
  - Proptosis helps to increase exposure
  - Quiets nystagmus (can be used for Yag laser w/ nystagmus also)
- Cons:**
- Blood thinners (+/- sev. studies show bleeding risk low for ASA & coumadin)
  - Monocular (RB injection can force admission until patch removed)
  - Risk of globe injury especially with long eyes
  - Tricky with patients following scleral buckle

Place 1 gtt of topical anesthetic into both eyes  
 Clean lower lid with alcohol wipe  
 Fill 5cc syringe with mixture of lidocaine/bupivacaine/widase **without** epinephrine  
 Place blunt 23 gauge needle on needle (blunt needle limits risk of globe perforation)  
 Start at the lateral lower lid about 3/4 of the way from the medial side  
 Use the index finger of non-dominant hand to create space between floor and globe  
 Aim perpendicular to lid until passing through the septum (1<sup>st</sup> pop)  
 Then redirect more superiorly advancing about 1 - 1½ inches (2<sup>nd</sup> pop) into muscle cone  
 First pull syringe back to ensure you are not in a blood vessel  
 Inject 4 cc slowly into retrobulbar space  
 Retract needle until just under skin to level of orbicularis mm  
 Inject remaining 1 cc to block facial nerve to prevent squeezing

Have patient look straight ahead during procedure

Apply pressure on closed eye for a minute or so – be alert for retro bulbar hemorrhage  
see video at: <http://www.facebook.com/video/video.php?v=38250571140>

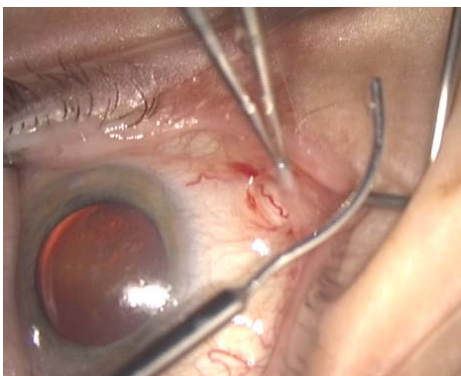

### Subtenon's Procedure

**Pros:** Great when Topical case is getting complicated (eg Convert to ECCE, ant vit)  
Great for pts on blood thinners to limit risk of retrobulbar injection

**Cons:** Conjunctiva gets red  
Post op foreign body sensation  
Conjunctival chemosis can be a problem

Give topical anesthesia (probably already done if converting from topical case)  
Prepare 3cc syringe with lidocaine/bupivacaine or use preservative free lidocaine  
Place lacrimal canula with gentle curve to approximate that of the globe  
(also can get Masket canula (or others) designed for this purpose)  
Pick a quadrant for the block (best to go for a lateral quadrant to avoid oblique mm)  
Have the patient look away from the chosen quadrant to increase exposure  
Use .12 forceps to retract conjunctiva  
Make small incision down to sclera with Wescott scissors  
Redirect Wescott scissors with curve down and bluntly dissect through quadrant  
Dissect past the equator (similar to using Stevens tenotomy scissors in peds/retina)  
Use .12 Forceps on posterior conjunctiva for counter traction  
Place canula through incision and direct past the equator before injecting  
Inject the anesthetic which should flow easily and cause minimal chemosis  
If anesthetic does not flow easily dissect further posterior with wescott scissors



## Topical Anesthesia

**Pros:** Experienced fast surgeon  
 Monocular patients get fast rehab  
 Great for long eyes to limit risk of injection  
 Decreased risk of retrobulbar bleeding injection (esp with Plavix>ASA>=coumadin)

**Cons:** Greenhorn surgeons need akinesia  
 Cannot use in patients with nystagmus

Intracameral: 1% nonpreserved lidocaine in anterior chamber can supplement topical  
 Many studies have shown no comfort benefit of intracameral  
 Helps with mydriasis  
 If the case is long or if iris is moving it seems to help in my hands  
 Usually placed just after paracentesis  
 Use about 0.5 cc of preservative free 1% lidocaine (can add epinephrine )  
 May sting a bit so I usually warn the patient:  
*"I'm giving you the rest of the numbing medicine and you may feel it for a second or two and then it will do its magic"*

Agent	Instructions	Pros	Cons
Tetracaine	1 gtt q 5min *3 15-30 min pre op	Cheap	Stings Epithelial toxicity
Tetracaine gel	Apply 15-30 min pre op	Better anesthesia	Stings Expensive May block prep
Proparacaine	1 gtt q 5min *3 15-30 min pre op	Cheap Less Sting	Less anesthesia Epithelial toxicity
Lidocaine gel	Apply 15-30 min pre op	Great anesthesia Easy	Can distort view Comes in large tube May block prep

## Cataract Surgery – Old School

**ICCE** intracapsular cataract surgery – lens with capsule removed

**ECCE** extracapsular cataract surgery -- lens removed and much of lens capsule left in place

- Planned ECCE done with expression of nucleus through large incision
- Manual Small Incision Cataract Surgery (**MSICS**) through self sealing incision
- **Phacoemulsification** ultrasound device breaks up nucleus through small incision

**PPLx** Pars plana lensectomy usually at time of vitrectomy for another problem

Method	Indications	Advantages	Disadvantages
ICCE	Weak zonules	No risk of secondary cataract Inexpensive	High risk vit loss (20%) Astigmatism Delayed visual rehabilitation AC or sutured IOL
ECCE	Very hard lens Poor K Endothelium	Least equip needed Easy on K endo Post chamber IOL	Astigmatism/sutures Delayed visual rehabilitation
MSICS	Very hard lens Poor K Endothelium Budget	Little astigmatism Quick visual rehab No sutures (usually) Inexpensive Easy on K endo Post chamber IOL	Incision is tough
Phaco	Most cataracts	Fast visual rehabilitation	Expensive instrumentation U/S can be hard on K endo Long Learning Curve
PPLx	Weak zonules During vitrectomy	OK if lens goes south	Expensive instrumentation Hard to place IOL in bag

### ICCE

Indications rarely indicated today – I do about one case a year  
Unstable lenses with severe zonular laxity

Be Careful children, capsular rupture, high myopia, Marfans, vitreous present

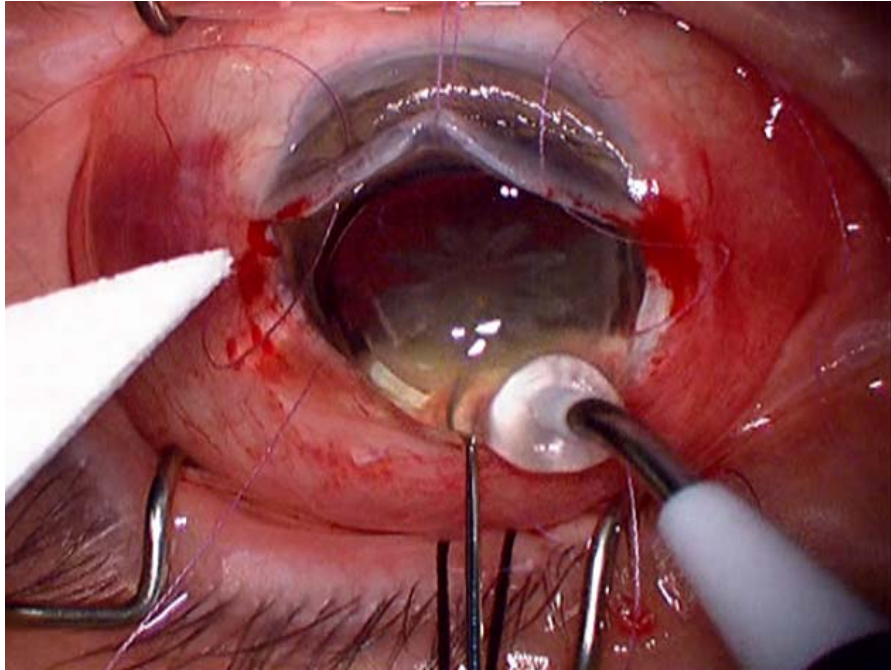
Pre-op: orbital massage or osmotic agents to reduce vitreous pressure

Anesthesia Retrobulbar and lid block  
Rarely general anesthesia, eg: claustrophobia, dementia, tremor

Procedure Superior bridle suture  
May need a scleral support ring in high myopes  
Peritomy of about 170 degrees  
Limbal incision of about 170 degrees chord length in the 11-12 mm range  
Safety sutures are preplaced – usually 7-0 vicryl  
Small peripheral iridotomy is placed



Alpha-chymotrypsin was placed to degrade zonules (no longer avail in US)  
 Anterior surface of the lens is dried with a cellulose sponge  
 Cryo probe is placed on mid-periphery of the lens and frozen  
 Lens is removed with a side to side motion through incision  
 Wound is closed with safety sutures  
 Vitreous is attended to if needed  
 Anterior chamber lens is placed after placing PI with anterior vitrector  
 Wound is closed with 10-O nylon



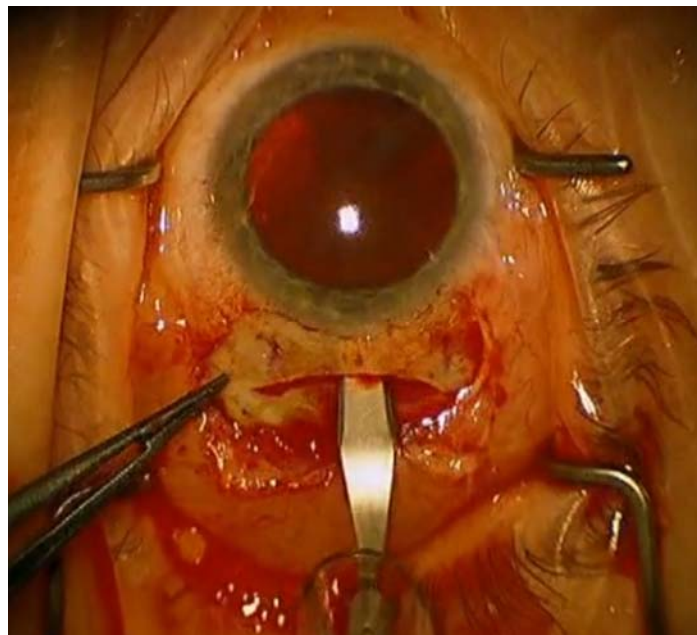
### Planned ECCE (w/ nucleus expression)

- |             |  |
|-------------|--|
| Indications | Still indicated today (small incision variant SICS very popular worldwide)<br>Hard lenses with tentative corneal endothelium   |
| Contraind   | poor zonular support, soft lens  |
| Pre-op:     | consider orbital massage or osmotic agents to reduce vitreous pressure   |
| Anesthesia  | Retrobulbar and lid block<br>Sub-tenon's block<br>Rarely general anesthesia, eg: claustrophobia, dementia, tremor  |
| Procedure   | Superior bridle suture<br>Peritomy of about 170 degrees<br>Initial limbal groove in sclera with a chord length in the 11mm range<br>Initial entry into anterior chamber to allow capsulotomy (3 mm)<br>Instill viscoelastic (see appendix 2)<br>Remove anterior capsule (usually with can opener approach)<br>Mobilize lens (physically with cystitome or with hydrodissection--be careful)<br>Extend initial incision to full length of groove (with scissors or knife)<br>Safety sutures are preplaced usually 7-O vicryl<br>Lens removed w/ lens loop or w/ counter pressure technique<br>Wound is closed with safety sutures<br>Cortical material is removed using I/A device (either automated or manual) |

Instill ophthalmic viscoelastic device (OVD)  
Lens is placed in the posterior chamber  
Wound is closed with 10-O nylon  
OVD is removed

## Manual Small Incision Cataract Surgery (MSICS)

Indications	Budget constrained Hard lenses with tentative corneal endothelium
Contraind	soft lenses
Pre-op:	consider orbital massage or osmotic agents to reduce vitreous pressure
Anesthesia	Retrobulbar and lid block Sub-tenon's block Rarely general anesthesia, eg: claustrophobia, dementia, tremor
Procedure	Superior bridle suture (if incision is superior) Peritomy of about 170 degrees Make frown shaped incision to reduce astigmatism Center of frown incision is 1-2 mm posterior to limbus Frown incision is 6-7 mm wide Incision dissection is carried into cornea widely to about 10 mm width Instill viscoelastic (see appendix 2) Initial entry into anterior chamber to allow capsulotomy with keratome Remove anterior capsule (large CCC, can opener, other) Mobilize lens (physically with cystitome or with hydrodissection with CCC) Lens removed w/ irrigating lens loop under lens Allow fluid pressure too push lens out of eye Cortical material is removed using I/A device (either automated or manual) Instill ophthalmic viscoelastic device (OVD) Lens is placed in the posterior chamber Wound may seal or use a couple of 10-O nylon sutures OVD is removed Reapproximate the conjunctiva



## Phacoemulsification – Step by Step

Please read Paul Koch ***Simplifying Phacoemulsification***  
 Bonnie Henderson, ***Essentials of Cataract Surgery***  
 David Chang: ***Phaco Chop*** and ***Curbside Consultation***

Indications Almost all cataract surgery  
 Contraind few, maybe: almost no zonular support or extremely hard lens

Anesthesia Topical +/- intracameral non preserved lidocaine, or  
 Retrobulbar and lid block, or  
 Subtenon's block  
 Rarely general anesthesia, eg: claustrophobia, dementia, tremor

Potential Complications	What to do about it
Retro-bulbar hemorrhage	Delay case and consider Canthotomy/lysis Check IOP
Inject/perforate eye ball	Delay case and cryo/laser area Pray, call risk management
Incomplete block	Carry on will get better Inject some more
Subconjunctival Heme	Forget about it

### 1) Rarely superior bridle suture (infraducts eye to allow superior exposure)

Potential Complications	What to do about it
Drive needle into vitreous	Delay case and cryo/laser area
Subconjunctival Heme	Forget about it

2) **Paracentesis** with #75 blade, or some other sharp knife, mark #75 w/ ink  
 Fixation with 0.12 forceps or with fixation ring  
 Paracentesis is relative to main incision so plan ahead  
 For Seibel chopper should be 60 degrees from main incision

Potential Complications	What to do about it
Put in wrong place	Make another
Too small	Make another
Too big	Suture later
Nick capsule	Include in removed capsule
Nick iris	Forget about it

3) **If topical instill lidocaine** (1% non-preserved in TB syringe w/ Troutman 27g)  
 Some debate about utility

Potential Complications	What to do about it
Stings	Re-assure patient
Put in wrong medicine	Wash out AC and pray Call risk management

Epithelial toxicity from topical	Coat w/dispersive OVD
----------------------------------	-----------------------

**4) Place ophthalmic viscoelastic device (OVD)**

Arshinoff shell technique: 1<sup>st</sup> dispersive (eg. viscoat), then cohesive (eg. healon)  
 Allows dispersive to coat corneal endothelium to protect from U/S energy  
 Allows cohesive to maintain chamber during the first part of procedure  
 Or use just one. Healon is cheapest at the our VA

Potential Complications	What to do about it
Shoot loose canula into eyeball	Tighten it better next time
Air bubbles	Suck out the air with syringe or place OVD distal and force out

**5) Wound – 3 major categories (very similar): limbal, scleral, and corneal**

Style	Advantages	Disadvantages
Limbal	Easy to convert to ECCE Instruments don't distort cornea Great for greenhorns	Induces astigmatism Always requires suture Iris prolapse more common Conj manip & cautery Eye is red after surgery
Scleral	Rarely induces astigmatism Seals nicely	Hard to convert to ECCE Technically difficult Iris prolapse more common Conj manip & cautery Instruments distort cornea Eye is red after surgery
Cornea	No cautery or conj. manip. Eye is white after surgery	Hard to convert to ECCE Technically difficult Instruments distort cornea Astigmatism with wide incision ?increased endophthalmitis

**Limbal**

Peritomy of 4-7 mm depending on IOL size  
 Cauterize sclera  
 ½ depth groove into limbus with crescent blade or 64 beaver  
 Enter eye with keratome (sized for phaco needle)

Potential Complications	What to do about it
Groove too deep	Usually no big deal W/iris prolapse move elsewhere
Nick capsule	Include in CCC'rhexis
Nick iris	Forget about it

**Scleral tunnel**

Peritomy of 4-7 mm depending on IOL size  
 Cauterize sclera  
 ½ depth groove into sclera with crescent blade

tunnel at 1/2 depth through sclera into cornea with crescent blade  
 enter eye with keratome (sized for phaco needle)

Potential Complications	What to do about it
Groove too deep	"is that ciliary body?" Close & move incision
Shred scleral flap	Tunnel further into cornea
Wound too wide	Partial suture to maintain AC
Nick capsule	Include in CCC'rhexis
Nick iris	Forget about it

## Corneal

1/3 depth tunnel into cornea with keratome  
 enter eye with keratome

Potential Complications	What to do about it
Shred flap	Move&/or suture
Too wide	Move &/or suture
Tunnel too long	Move or re-enter shorter Funnel internal section wider
Tunnel too short	Suture and move Use iris hook under wound to prevent iris prolapse
Start too posterior	Peritomy to prevent conj donut
Nick capsule	Include in CCC'rhexis
Nick iris	Forget about it
Descemet's detachment	Place air and position head to tamponade Place SF6 gas (1/3-1/2 AC)

## 5) Capsulorhexis

### Most important part of the procedure

Anterior chamber must be filled with viscoelastic

2 basic techniques continuous curvilinear capsulorhexis (CCC) and can opener

Style	Advantages	Disadvantages
Can opener	Easy to do Red reflex not required Allows ECCE nucleus expression	Increased risk of vitreous loss IOL is less stable Increased risk of PCO
CCC	Less risk of vitreous loss IOL is very stable Less PCO	Hard to do May need capsular stain w/poor red reflex Needs relaxing incisions for ECCE

**Goal** is CCC with a central circular opening slightly smaller than the optic diameter  
 3 basic techniques for CCC (best way to learn about this is to watch video)

- cystitome - initial cut and control of tear with cystitome (best with cohesive OVD)

- combo - initial cut w/cystitome, most of tear w/ forceps (most common technique)
- forceps- sharp forceps cut and then grab capsule to complete tear
- femto second laser -- cheating

Potential Complications	What to do about it
Poor red reflex	Capsular stain eg trypan blue Side light with corneal opacity
Starting to go radial	Add OVD – most important Grab close to tear and redirect Little technique – pull flap in opposite direction then central and tear will often turn back
Radial tear	Use scissors to restart in other direction Relaxing tear 180 across Can opener and conversion to ECCE De-bulk sculpting out bowl prior to hydrodissection Wide groove, divide, prior to hydrodissection V groove with no hydrodissection
Too small	Enlarge after placing IOL
Too large	Forget about it Nucleus may easily prolapse during hydrodissection
Zonular laxity	Use iris or capsule hooks to stabilize Use iris hooks with CTS to stabilize Early capsular tension ring (w or w/o cionni mod), Sutured capsular tension segment (CTS) Place CTR or CTS after cohesive viscodissection

## 6) Hydrodissection

Second most important of procedure

Skip with posterior polar, perforating lens trauma or early post vitrectomy cataract

Balanced salt solution in 3 cc syringe with troutman 27 g or similar

little waves of these steps

Inject fluid just under capsule to cleave cortex from capsule

Gently press on lens

Look for a fluid wave. Don't stop till you get enough. Don't stop till you get enough

Rotate lens to ensure the job is done

May prolapse lens with a large capsulorhexis – not always bad.

Potential Complications	What to do about it
No fluid wave	Try again in different spot Increase force Use bursts and gently push on nucleus between bursts
Iris Prolapse	Release AC pressure thru paracentesis Rock lens to release BSS trapped in bag and free posterior pressure Prevent by removing dispersive OVD over lens and iris before hydrodissection

	sub-incisional iris hook
Prolapse nucleus	Brown tech. or Pop n Chop Flip into ciliary sulcus Push back into bag
Blowout post capsule	Too late but was this? s/p vitrectomy, trauma or post polar cataract Clean up the Vit in AC, Place IOL Call your friendliest Vit surgeon (this is their job don't worry about it)

## 7) Phacoemulsification

Goal is to remove lens with the minimum ultrasound (u/s) damage to the cornea  
Trend is to use increasing vacuum and decreasing u/s power to remove nucleus  
Energy can be torsional (Alcon, AMO) or longitudinal (standard u/s)

Energy	Advantages	Disadvantages
Torsional (eg Ozil)	Material flows to tip May be cooler	Tip can become occluded Bored hole larger than tip
Longitudinal (traditional)	More power Nice to bore for occlusion Nice for grooving	Pushes material away from tip May be hotter

Phacoemulsification of the nucleus can be done:

- Endocapsular – keeping the nucleus in bag during phaco
- Supracapsular – prolapsing nucleus into sulcus during phaco
- AC shell - prolapsing shelled out nucleus into AC
- ½ bag ½ AC --tipping nucleus on side ½ in bag; ½ in AC.—Brown, Pop-n-Chop

Phaco Location	Advantages	Disadvantages
Endocapsular	Energy away from cornea	Tear ant capsule with chopper or phaco tip Nuclear pieces tight in bag – Jigsaw puzzle problem
Supracapsular	Less risk of hitting ant cap No jigsaw problem	U/S energy close to cornea Nuclear flip close to cornea
AC shell	Little stress on bag	Slow Energy close to cornea Old school
½ bag ½ AC	No jigsaw problem Less risk of hitting ant cap	Energy closer to cornea

Many ways to disassemble nucleus

- Sculpting out a bowl and then collapsing material into center
- Divide and conquer—classic technique, must know
- V groove -- old school useful when hydrodissection is not possible
- Chopping – horizontal chop, vertical (quick) chop, stop n chop

Fragmentation Style	Advantages	Disadvantages
Sculpt and Prolapse	Can do with one hand	Slow Energy close to cornea Lots of u/s power
Divide and Conquer	Classic easy to do Energy away from cornea Can do with one hand	Lots of u/s power
V groove	Does not require hydrodissection Does not require rotation Useful with known capsule damage	Slow Lots of u/s power
Stop n Chop	Fairly easy to do Less u/s power	Needs two hands
chop	Little stress on bag Least u/s power Fast Easy on zonules	Hard to do Needs two hands hit ant capsule with chopper Jig saw problem

Potential Complications	What to do about it
Chamber Instability Post occlusion surge	Increase bottle height Decrease vacuum (and flow rate w/peristaltic) Check irrigation tubing for kinks Wounds too big? -- suture end
Tear anterior capsule	Carefully proceed, or Consider conversion to ECCE Consider V groove technique
Tear posterior capsule	Strongly consider conversion to ECCE, or Clean up the Vit in AC, place OVD, consider continued phaco (advanced) Use IOL as scaphold Don't let the AC shallow use OVD if possible
Pieces won't come to tip	Increase aspiration flow rate and vacuum Reprime vacuum (esp w venturi system) Check aspiration tubing Add longitudinal phaco (tip occluded) Remove second instrument esp if paracentesis is leaky
Wound hot	Widen wound and continue Stop lifting up on needle Clear out OVD (especially dispersive) Suture at end (may need horizontal mattress)
Shallowing of chamber	Fluid out > in so check lines, wounds, bottle choroidal hemorrhage – check red reflex misdirected BSS posteriorly—wait it out fluid trapped under lens -- rock it to release



## 8) Cortical Aspiration

Aspiration to grab and peel the cortex off the capsule not suck it off the capsule  
Dangerous procedure – common time for Vitreous loss in experienced surgeon  
Sub-incisional removal is most difficult esp with small rhexis  
Adequate hydrodissection makes this step easier

Potential Complications	What to do about it
Chamber Instability	Increase bottle height Check Tubing and fluid level of BSS bottle Wound too big? -- suture end Decrease vacuum or flow rate (peristaltic)
Catch posterior capsule “Spider sign”	Reflux fluid Continue and keep aspiration port up
Grab capsule and tear zonules	Capsular tension ring Place 3 piece IOL haptics in area of weakness CTS if zonular loss > 3 clock hours Place dispersive OVD in weak area
Tear capsule	Don't let the AC shallow use OVD if possible Anterior vitrectomy Convert tear into continuous circular tear (rare) Dry removal of residual cortex with canula Consider sulcus IOL Miochol at end of case
Residual Subincisional Cortical material	Hydrodissect area through paracentesis; try again Use 90 degree angled I/A handpiece Place OVD and carefully use J cannula Place IOL and use optic to shield capsule try again

## 10) Fill Bag with OVD

Form Bag not Sulcus  
Use cohesive OVD in bag  
Consider dispersive OVD adjacent to wound to seal – Arshinoff Shell -- \$\$  
Place OVD ahead of the canula -- don't pierce the post capsule with canula  
Make sure the canula tip is firmly attached to syringe or it will shoot off

## 11) Wound may need to be extended to allow placement of the lens

PMMA (doesn't fold) IOL needs slightly more than optic size  
Old school now forcep loaded IOLs needs 3.5 or so to insert  
Most injected IOL's don't need extension from incision for phaco needle  
Well constructed wound a bit bigger seals better than stretched small wound

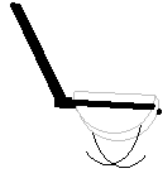
## 12) Lens is placed into capsular bag

PMMA IOL  
Grasp IOL and trailing haptic with forceps (e.g. Kelman-McPherson)  
Place leading haptic into bag; optic into AC; release forceps

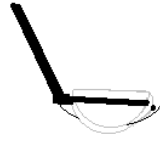Place optic into bag  
 Place trailing haptic into bag with hook or forceps

**Folded IOL**

Folded and placed in special forceps  
 Incision size grows a bit with increased power of IOL – 3.5 mm range  
 Moustache style fold: wider incision but haptics flow into bag (great when suturing IOL to the iris with no capsule)  
 Axial style fold: smaller incision but haptics need guidance



Moustache




axial

**Injected IOL**

Most common -- many different systems  
 Single piece acrylic (SA 60, SNWF) and plate IOL most simple  
 3 piece IOL requires some haptic care and manipulation  
 Be careful of Descemet's membrane w/IOL insertion (especially w/injectors)



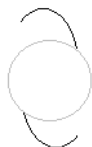
Toe up on injector can tear Descemet's membrane



Toe down slips under Descemet's membrane

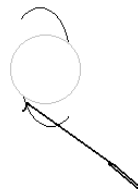
**Is the IOL right side up?**

Correct side up looks like 7 O Leven (have you heard of 7-11 stores?)



Top haptic looks like a **7**  
 Optic looks like an **O**  
 Bottom haptic looks like an **L**

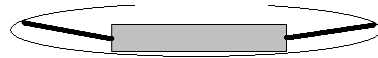IOL is designed for right handed surgeon to easily rotate



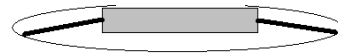When upside down the IOL looks like an **S** so **Stop**



Upside down angulated 3 piece IOL creates myopic shift w/anterior IOL shift



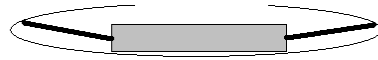Right side up



Upside Down

### **Make sure that both Haptics are in the Bag**

May need to add OVD – often some is lost during insertion of IOL  
Most common cause of decentration: one haptic in bag; one in sulcus  
Bag has less space than sulcus – ½ in IOL shifts toward sulcus haptic



centered in bag



decentered ½ in bag

### **Rotate IOL so that Haptics are 90° from the wound**

Set yourself up for the next step – irrigation and aspiration I/A  
Allows I/A tip to get under IOL to remove OVD under IOL  
Frees most common site of residual cortical material from haptic

### **Special IOL Placement Conditions**

#### **Anterior Capsular Tear**

Single piece acrylic in the bag – creates little tension on the bag  
3 piece with both haptics in the sulcus

#### **Zonular Dialysis**

Capsular Tension Ring with any IOL  
3 piece IOL with PMMA haptic oriented toward weak area of zonules  
Consider CTS

#### **Posterior Capsular Tear before IOL is placed - stable or round hole**

Dispersive OVD in the post capsular hole -- gently place IOL into bag  
Place 3 piece IOL in sulcus +/- capture of optic by centered CCC

#### **Posterior Capsular Tear before IOL is placed - large tear**

Dispersive OVD in the post capsular hole  
Place 3 piece in sulcus +/- capture of optic by centered anterior CCC

#### **Posterior Capsular Tear after 3 piece IOL is placed in bag (rare)**

Dispersive OVD in the post capsular hole  
Gently move 3 piece IOL into sulcus  
Consider capture optic by centered anterior CCC  
If sulcus is not stable then use iris sutures

#### **Posterior Capsular Tear after single piece IOL is placed in bag (rare)**

Dispersive OVD in the post capsular hole  
Gently prolapse optic anterior and capture with CCC (if possible)  
If CC is not stable remove IOL and replace with 3 piece in the sulcus

### No Capsular Support

AC IOL 3 sizes depending on white to white size (simple)

Iris Sutured PC IOL (need to know how to do this)

Scleral Sutured PC IOL

Classic Wagoner AAO study no difference in the above

Agarwal technique with haptics in scleral pocket with glue

Iris Clip IOL (Artisan – not approved by FDA for aphakia yet)

Potential Complications	What to do about it
Place IOL up-side down	Can leave as is – accept myopic shift, or Take one haptic out of wound with hook Fill with OVD above and below IOL One hook above and one below -- Flip IOL
Inadvertent sulcus placement	Fill with OVD -- Rotate into bag with hook If a 3 piece can leave in sulcus w/myopic shift Do not leave single piece acrylic (SA60) in sulcus
IOL doesn't center	Usually one haptic in sulcus one in bag dial both into bag or both into sulcus Possible zonular dialysis if nearly centered leave it alone rotate IOL carefully for best centration w/3 piece often haptics best at weak area check wound for vitreous consider late placement of CTR or CTS place miochol to help check for vitreous Haptic damage (especially with 3 piece IOL) may have to replace IOL could capture with centered anterior capsule
Tear in Descemet's	Use care to not extend tear Place Air Bubble at end of case – post op position wound up -- bubble seals tear
Marred IOL	If not central forget about it If central exchange IOL
Lens Material behind IOL	Rotate haptic 90 deg from wound Toe down with I/A and get under IOL With asp hole showing at all times aspirate

### 13) Sutures are preplaced (if needed)

Pre-place 10-0 nylon sutures while OVD maintains chamber

Usually need 2 interrupted or one X suture with 6 mm scleral tunnel

Usually need 1 interrupted suture with 3 mm limbal wound

Usually need no sutures with proper 3 mm wound of cornea or sclera

Can use 10-0 vicryl sutures with children

### 14) OVD is removed with I/A device

As always keep aspiration port up

Go under IOL to remove OVD, esp if you have been having IOP problems post op

Potential Complications	What to do about it
Chamber Instability	Increase bottle height Check Tubing and fluid level Wound too big? -- suture end Decrease vacuum
Catch Iris	Reflux fluid Continue and maintain your bearings
Grab capsule and tear zonules	Capsular tension ring Place dispersive OVD in weak area

### 15) Sutures are tied

3/1/1 for 10-0 nylon in the sclera

2/1/1 for 10-0 in clear cornea to allow small knot to rotate and bury

### 16) Other

Give antibiotic drops rarely subconjunctival antibiotics

Consider postoperative povidine iodine

Consider lubricating cornea w/dispersive OVD (eg ocucoat )

Patch to protect cornea if retrobulbar or subtenons was used

# Phaco Machine Settings Primer

## Four main components and software to tie them together

Pump – most important variable

Parameters depend on tubing diameter and compliance

Parameters depend on phaco needle diameter

Allows removal of the emulsified lens material

Set low during sculpting and higher during quadrant removal and chopping

Irrigation System

Typically is just an adjustable bottle held higher than eye to allow infusion of fluid

Machine can adjust bottle height

Machine can turn fluid on and off

Ultrasound (U/S) hand piece

Vibrates needle at a set rate in the 20,000 to 40,000 Hz range

Increasing the U/S power increases the excursion of the needle not frequency

With increasing load (eg big hunks of lens) the frequency/excursion may not keep up

Modern multiple crystal hand pieces can better handle load

Some machines (eg lacon and AMO) have both longitudinal and torsional power)

Footswitch

Typically controlled with dominant foot (w/o shoes)

Accelerator like pedal is common across all brands

Position 0 – everything is off

Position 1 – irrigation is on, no pump, no U/S

Position 2 – irrigation is on, pump is on, no U/S

Position 3 – irrigation is on, pump is on, U/S is on

## Phaco Pumps

Look over the classic definitive text: Barry S. Seibel, *Phacodynamics*, Slack

**Flow rate:** amount of fluid passing through the tubing (cc/min) also aspiration flow rate

**Vacuum:** difference in fluid pressure in two points eg tip of needle and AC (mm Hg)

**Vacuum based Pumps** – eg. Venturi pump (Stellaris, *Accurus*), diaphragm

Increasing pump power increases vacuum directly; flow rate indirectly

Venturi pump requires external source of compressed air or compressor

This has limited acceptance of this pump (ASC may not have air lines)

Compressed gas flows over open top of rigid cassette attached to tubing

Flow of gas creates vacuum much as flow over airplane wing creates lift

Flow rate is a function of vacuum and resistance of flow and not directly set

Roughly analogous to electric current voltage relationship (Ohm's law)

$i=e/r$  where  $e$  = voltage (analogous to vacuum)

$i$  = current (analogous to flow rate)

$r$  = resistance (analogous to tubing and occlusion)

more flow (cc.min) with less resistance (fixed vacuum)

more flow (cc/min) with more vacuum (fixed resistance)

Pump settings -- No settings for flow rate only vacuum

Fixed: no matter how deep you are in position 2 or 3 vacuum is fixed

Great for chopping and quadrant removal

Variable: vacuum increases from 0 to max as you push on the pedal  
 Great for i/a can slowly increase vacuum to just what you need

**Flow based pumps** – eg. peristaltic pump (*Infinity, Sovereign, and Legacy*)

Increasing pump power increases flow rate directly and vacuum indirectly

Vacuum is dependant on resistance of flow

Roughly analogous to electric current voltage relationship (Ohm's law)

$e=ir$  where e = voltage (analogous to vacuum)

i = current (analogous to flow rate)

r = resistance (analogous to tubing and occlusion)

more vacuum with more resistance (fixed flow rate)

more vacuum with more flow rate (fixed resistance)

**Pump Settings**

Set vacuum cutoff and flow rate

Vacuum cut off

Seems like you are setting the vacuum

Really setting the vacuum at which the pump stops

Increasing the vacuum does not increase pump speed

Flow rate or Aspiration FR rate (AFR) sets pump speed cc/min

W/modern peristaltic pumps (eg. *Infiniti*) for each foot pos you can have

Fixed or variable flow

Fixed or variable vacuum cut off

Flow rate	Vacuum Cut off	Comment/Application
Fixed	Fixed	Independent of depth in foot position Low numbers good for sculpting
Fixed	Variable	More depth higher vacuum cut off Limited control Typical I/A setting on <i>Alcon 20,000</i>
Variable	Fixed	More depth faster pump More control pump speed changes Bimodal setting on <i>Alcon 20,000</i>
Variable	Variable	Both change with depth in foot pos. Feels like a venturi pump

**Phaco Pump Comparison**

Pump	Pros	Cons
Vacuum Eg Venturi	Less post occlusion surge Better for vitreous removal Material comes to tip easily	Need source of compressed gas Need rigid cassette
Flow Eg. Peristaltic	Better for sculpting No need for compressed air	Post occlusion surge Need occlusion for vacuum to build

**Ultrasound Control**

Four axial ultrasound modes: continuous, pulse, burst, and hyperpulse;

Now some machines also have some rotary (Ozil on infinity) or oscillatory (AMO) motion

**Continuous**

Phaco is on in position three

Usually increasing u/s power with depth into foot position 3

**Pulse**

Phaco pulses with duty cycle on and off

Usually with equal on and off time or 50% duty cycle (time on/cycle time)

Usually the rate is fixed (Hz)

Usually increasing u/s power with depth into foot position

**Burst**

Bursts of power come with off time that decreases with depth into foot position

Usually when floored in position 3 -- u/s power becomes continuous

U/s power is fixed

**Hyperpulse**

Uses short on time pulses eg 25% on; 75% off

Fixed duty cycle; fixed pulse rate; usually high frequency like 200 hz

Usually increasing u/s power with depth into foot position 3

**Torsional (eg Ozil or AMO oscillatory)**

Ozil uses rotary motion of angled (Kelman type) tip rather than longitudinal u/s power

AMO oscillatory system does not require Kelman tip

can use supplemental longitudinal to clear and prevent occlusion

Mode	Advantages	Disadvantages	Applications
<b>Longitudinal</b>			
Continuous	Simple	Repels nuclear material Hot	Sculpting
Pulse	Less hot	Can repel nuclear material	Choo choo chop Segment removal
Burst	Less hot Holds material well		Chopping
Hyperpulse	Followability w/Long off cycle Cool with long off cycle		Sculpting Bimanual small incision
<b>Torsional</b>			
Continuous	Followability (doesn't push material away) May be cooler	Can get clogged Additional expense	Just OK for Chop Great for Segment removal



## My Typical Settings

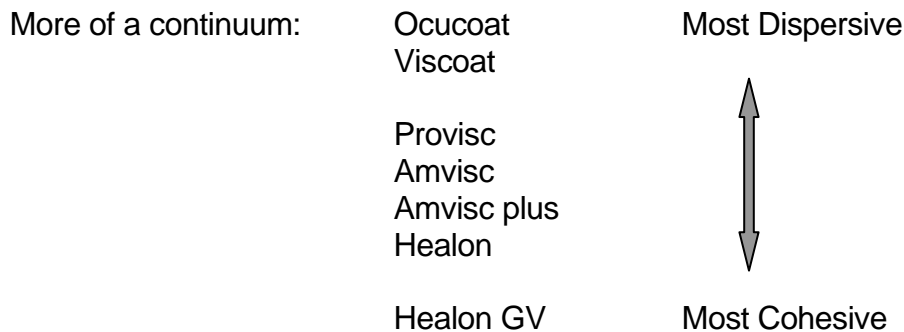
<b>Millennium</b>	Vacuum	Type	Flow	U/S	Comment
Sculpt	15		n/a	Continuous	
Segment removal	100-150		n/a	Pulse 4 Hz	2 <sup>nd</sup> yr at 100; 3 <sup>rd</sup> yr at 150
Chop	150		n/a	Pulse 4 hz	Choo choo chop
i/a	500		n/a	n/a	Default settings
<b>Stellaris</b>	Vacuum	Type	Flow	U/S	Comment
Sculpt	15		n/a	Continuous	
Segment removal	175		n/a	Pulse 60 Hz 30% On	
Chop	175		n/a	Pulse 4 hz	Choo choo chop
i/a	500		n/a	n/a	Default settings
<b>Alcon 20,000 Legacy</b>					
Sculpt	50		22	continuous	
Segment removal	40		400	Pulse 4 hz	Good 3 <sup>rd</sup> yr settings
Chop	40		400	Burst	Could increase to 50/500
Epinucleus removal	30		300	bimodal	
i/a	500		50	n/a	Default settings
<b>Alcon Infinity</b>					
Sculpt	80 F	longitudinal	20 F	Hyperpulse	continuous
Grab for chop	350 F	longitudinal	35 F	Burst	50 ms
Remove Pieces	350 F	Ozil	35 F	Continuous	
Epinucleus removal	300 V	Ozil	30 F	Continuous	
i/a	500+ V		50 V	n/a	Default settings

# Ophthalmic Viscoelastic Devices (OVD)

## Two basic categories:

**Cohesive:** high molecular weight, high surface tension, eg: healon  
Big, bulky, and likes to touch itself

**Dispersive:** low molecular weight, low surface tension, eg: viscoat  
Smooth and likes to touch others



## Different jobs demand different OVDs

1. Maintain space: eg. AC during rhexis bag during IOL insertion      cohesive best
2. Create space: eg. Creating sulcus shift lens material      cohesive best
3. Sealing off: eg. Sealing capsular tear keeping iris tag away      dispersive best
4. Coating: eg. Protect corneal endothelium lubricate cornea      dispersive best

Step	Cohesive	Dispersive
CCC	Easy to fill AC Can suddenly lose OVD through wound	Must completely fill AC Stays in AC
Phaco	Goes away with first vacuum	Stays on endothelium Particles can stick to endothelium Increased risk of burn
IOL insertion	Easy to open/maintain bag Easy to remove material	Hard to remove residual material

**Removal**      Dispersive harder to remove  
                          Short molecules don't string along together into port during I/A  
                          but short molecules create less post op IOP spike  
                          Cohesive is easier to remove  
                          Longer molecules string along together into port during I/A

Longer molecules block the trabecular meshwork for big IOP spike

### **Adaptive OVD (eg Healon 5)**

Properties of dispersive OVD at high shear rate (eg. during phaco)

Properties of cohesive OVD at low shear rate (eg during IOL placement)

Very long fragile chain molecules that break with flow rate

Difficult to remove

### **Arshinoff Shell**

Phase I during CCC

First place dispersive OVD (magenta below)

Then place cohesive OVD just over lens (blue below)

Then dispersive is pushed up to coat endothelium

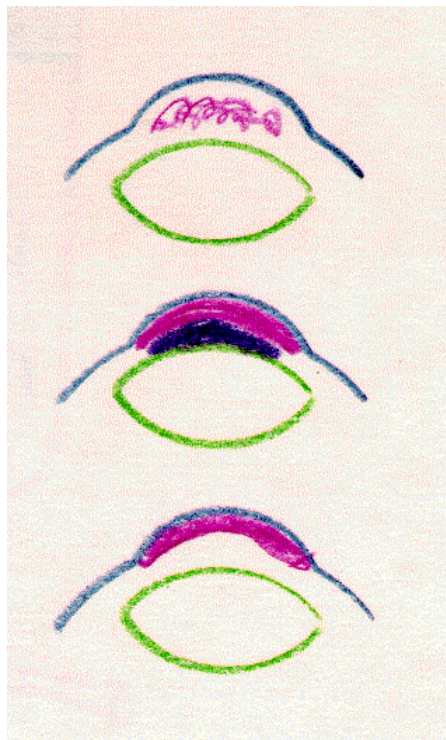
As soon as phaco starts cohesive is aspirated and dispersive coating remains

Phase II during IOL insertion

First place cohesive OVD in the bag

Then place dispersive OVD just inside wound to seal prior to IOL placement

When IOL is inserted dispersive helps to keep cohesive in place; bag formed



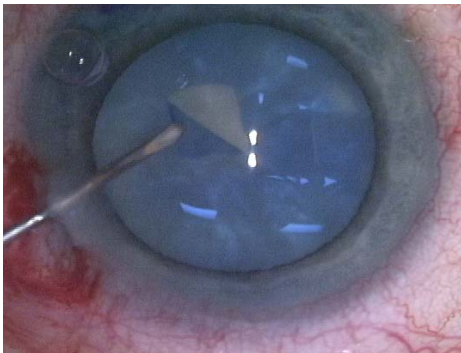
## Capsular Staining

The white cataract used to be the most feared cataract surgery to perform  
Capsular staining has changed these cases from complex to routine  
Capsular stains (ICG and trypan blue) are useful whenever capsule is hard to see

- Classic white cataract
- Traumatic cataract with possible anterior capsular tear
- Dark red or brown cataract with limited red reflex
- Started rhexis and then loose capsule in an area of dense lens
- Useful for delineating anterior capsular trauma

### Trypan Blue (*Vision Blue*)

Premixed and approved by the FDA (2005) making it cheaper, better, and faster than ICG



### Indocyanine Green (ICG)

ref: Horiguchi, "Staining ...", Arch Opth. 1998; 116:535-537.)

ICG is used to stain the lens capsule but is rarely used with Trypan Blue available now  
Stain may be harmful to the retina so use the least amount possible

Preparation:

- Draw up 0.5 cc of aqueous solvent (comes with ICG) into syringe
- Place aqueous solvent into vial of 25mg ICG and shake
- Draw up 4.5 cc of BSS into syringe
- Place BSS (original article was BSS+; but BSS OK) into ICG vial and shake some more
- Osm 270 (plasma 285) with a concentration 0.5%

### Surgical Technique for either stain

- place paracentesis and fill anterior chamber with air
- Can place some dispersive OVD at wound if air leaks
- Drop/rub ICG solution or Trypan Blue onto anterior capsule w/cannula
- wash out stain with BSS through paracentesis and remove bubble
- Fill anterior capsule with OVD
- Make typical wound into anterior chamber
- Perform CCC (capsule will be green or blue, lens will not)

**Remember** that you can add stain later if you need more or if you realize that you would be helpful even after you have gotten started.

## Routine Post Operative Care

### Phacoemulsification

Usually 2 or 3 post operative visits

- same afternoon 4-6 hours later (to catch IOP peak) or next AM
- (optional) one week later (to check on inflammation)
- 3-4 weeks later to give glasses

#### First Visit

RAPD, VFF to CF

VA expect about 20/40 better w/PH

SLE expect corneal edema proportional to ultrasound time

expect epitheliopathy from the topical anesthetic

1-2+ cell and flare

look for K abrasion especially if patched

look for retained material in inferior angle

IOP if < 8 look hard for leak with Seidel test

if 9 – 29 probably OK

if > 30 start with cosopt, alphagan recheck in 45 min

if > 40 suppress aqueous and bleed aqueous through  
paracentesis until pressure is stable <30

recheck in 45 minutes or so consider seeing the next day

lower these guidelines in patients with h/o DM, AION, etc

usually can see fundus w/o dilation document no RD or choroidal

plan antibiotic i gtt qid for a week

prednisolone acetate taper i gtt qid for a week, then tid for a week...

f/u 2-4 weeks later in routine cases

one week later with IOP spike, vitreous loss, h/o uveitis

next day with wound leak, big corneal abrasion, etc...

give a simple large print post operative instruction sheet

#### Week #1

RAPD, VFF to CF

VA expect about 20/30 PH 20/20

SLE expect little corneal edema and trace to 1+ cell and flare

Consider fundus exam with poor vision, DM, floaters, etc..

plan taper prednisolone acetate

stop antibiotic

f/u usually 3-4 weeks later

full activity

#### Week #2-4

RAPD, VFF to CF

VA expect about 20/25 PH 20/20

MR consider suture induced astigmatism

plan give MR for glasses f/u 1 year

## large incision ECCE or ICCE

Usually at least 3 post operative visits

- same afternoon 4-6 hours later (to catch IOP peak) or next AM
- one week later (to check on inflammation)
- 4-5 weeks later to check astigmatism for suture removal or give glasses

Much of the emphasis is on suture removal for astigmatic control

### Day #1

RAPD, VFF to CF

VA expect about 20/200 better with PH

SLE expect significant corneal edema  
2-3 +cell and flare

look for K abrasion esp if patched

IOP if < 8 look hard for leak with Seidel test

if 9 – 29 probably OK

if > 30 start with cosopt, alphagan recheck in 45 min

if > 40 suppress aqueous and bleed until pressure is stable <30  
consider seeing the next day

lower these guidelines in patients with h/o DM, AION, etc

usually can see fundus without dilation document no RD or choroidal

plan floroquinolone i gtt qid

prednisolone acetate i gtt qid

cyclogyl 1% bid

f/u one week later usually

next day with wound leak, big corneal abrasion, etc...

give a post operative instruction sheet

### Week #1

RAPD, VFF to CF

VA expect 20/100 and about 20/50 w/PH

keratometry for fun -- expect about 7 diopters

don't waste time with refraction

SLE expect little corneal edema and 1-2+ cell and flare

usually can see fundus when on cyclogyl document no RD

plan d/c antibiotic (tell pt. to keep bottle in refrigerator for suture removal)

d/c cyclogyl if inflammation is less than 1+; o/w continue

taper Prednisolone: i gtt qid for 7 more days, then

i gtt tid for 7 days, then

i gtt bid for 7 days, then

i gtt qd for 7 days, then

discontinue

f/u 5 weeks later (allows healing time before suture removal)

**Week #6**

RAPD, VFF to CF

VA expect 20/80 and about 20/40 w/PH

keratometry expect about 5.0 diopters at 90

don't get confused and read backwards

eg. for 5.0 at 90: left dial could read 40 right dial reads 45

MR Start with streak retinoscopy or auto refract (usually on w/clear media)

Start with 2/3 of cyl from K's and adjust SE to -1.0 (usually very close)

SLE look at the wound and decide which sutures look tight

suture lysis Indicated when cyl is  $\geq 2$  diopt. on MR, or $\geq 3$  on K's (if you did not do MR)

if less than 2 on MR, stop, high fives, don't cut anything

remove tightest suture near axis of cylinder on K's

only cut one suture at week 6-8 visits

can cut two beyond week 8

if tight axis is between sutures cut both (think vectors)

plan full activity

antibiotic drop i gtt qid for 4 days (following each suture removal)

f/u if no sutures need to be removed (will never happen)

give glasses -- usually +2.5 add with MR

f/u 1 year.

otherwise return every 1-2 weeks for additional suture lysis

**After that**

you really have about three three choices (don't stall):

1) pull a stitch (i.e. cyl at axis of stitch is greater than 2 on MR)

2) give glasses (i.e. no stitch to pull or cylinder is less than 2 on MR)

3) get OCT because you suspect CME

don't waste time thinking about other possibilities

not everybody is going to be 20/20.

## Principles of Anterior Vitrectomy

We will cover the causes and signs of vitreous prolapse and the principles of anterior vitrectomy in various situations<sup>1-3</sup>. This handout is modified from my blog<sup>1</sup> which also includes video and may be of some interest to those learning about anterior vitrectomy.

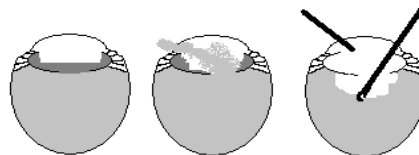**Causes of vitreous prolapse.** The vitreous either comes around the zonules or through a tear in the posterior capsule. Posterior capsular tears are caused commonly by: anterior tear extending posteriorly (most common), posterior tear secondary to phaco needle being too deep too deep, a chopper or from the I/A instrument, or a pre-existing injury ( eg. posterior polar cataract iatrogenic from PPVx, or from penetrating lens trauma). Zonular problems are often pre-existing such as from trauma, PXF, or Marfan's but can also be iatrogenic from forceful rotation of the lens or pulling on the capsule during I/A.

**Signs of vitreous prolapse.** The first sign of vitreous prolapse is denial. Something seems wrong but you can't quite pin point the issue. At first you deny that an issue exists but soon it becomes clear. Less mysterious signs of vitreous prolapse include: the chamber deepens, the pupil widens, lens material no longer centered, particles no longer come to phaco or I/A, and the lens no longer rotates freely. When you suspect vitreous prolapse you should keep the chamber formed by placing dispersive OVD into the eye before removing the phaco needle or I/A from the eye and can check the wound with a Weck sponge for vitreous.

**Principles of anterior vitrectomy.** The key to a successful anterior vitrectomy is to control the fluidics of the eye. The first step is to close the chamber. Resist the temptation to use the larger phaco wound for the vitrector; instead make a new paracentesis just big enough for the vitreous cutter. You may need to close the original wound if it is not well constructed but usually you will not need to suture the original wound as long as it stays water tight during the anterior vitrectomy.

The second step is to separate the irrigation device from the aspiration/cutting device (this is standard on modern phaco machines). In general you will want to place the vitreous cutter low (at the level of the posterior capsule) while holding the irrigating canula high (anterior chamber) which allows you to create a pressure differential such that the vitreous is encouraged to move posteriorly toward the aspiration/cutter and away from the anterior chamber.

- Close the chamber
- Separate irrigation and cutter
- Cut low/Irrigate high



In general the bottle height should be low – just high enough to keep the AC formed and not so high that fluid is forced out around the instruments which can bring vitreous with it. The smaller the bore of the infusion canula the higher the bottle height will need to be. The higher the vacuum the higher the bottle height will need to be. The cutting rate should be as high as possible when cutting vitreous and low when cutting cortical lens material or removing viscoelastic. We will separately discuss early, mid, and late case vitreous loss below.



## **Vitreous Presenting early in case –while most of crystalline lens is in eye**

This is the worst time for vitreous to prolapse. The strategy will depend on how the vitreous presented. If the vitreous has come from a strike in the posterior capsule while grooving or from a radial tear which has gone posterior with almost all of the lens remaining then one should strongly consider converting to ECCE. If the pieces are smaller then another option is to sequester the residual nuclear material with viscoelastic or an IOL scaffold<sup>5</sup>, perform the anterior vitrectomy, and continue with slow motion phacoemulsification<sup>6</sup>. If the vitreous has come from loose zonules then the solution may be better support of the capsule with a capsular tension ring (CTR), a capsular tension segment (CTS), or capsular hooks.

### **Conversion to ECCE for early vitreous loss**

- If topical consider adding a subtenons injection. incise conjunctiva in a quadrant and dissect posterior to the equator and place 2 cc non preserved lidocaine behind the eye.
- Use only viscous dispersive viscoelastic (eg Viscoat) from this point forward as it causes less ocular hypertension and sticks to other structures.
- Consider closing the temporal incision with 10-0 nylon and make a separate incision with peritomy superiorly or extend the existing temporal wound along the limbus to about 6 mm (if nucleus is already in quadrants) or 11 mm (if whole)
- Use viscous dispersive viscoelastic (eg Viscoat) to lift lens up near the wound and to displace the vitreous more posteriorly.
- May need weck cell vitrectomy to clean up the wound if the vitreous has presented through the main wound. viscoelastic may help push vitreous out of wound.
- Use lens loop to remove residual lens material
- Have Wescott scissors ready when looping out lens to cut vitreous
- Close with 7-0 vicryl safety sutures. For 11 mm wound use 3, one at center and one on either side 3 mm away (allows removal of center suture to place 6 mm IOL)
- May need to add some 10-0 nylon at wound edges to get watertight
- Bimanual closed chamber anterior vitrectomy (as above)
- Dry removal of residual cortical material with syringe on standard 27 gauge canula or use 23 gauge visitec cortex extractor canula. can also viscodissect cortical material
- Use J-cannula or paracentesis if needed for sub-incisional material
- Consider staining vitreous with triamcinolone (see below)
- Place IOL if possible in sulcus (adjust power) or use an AC IOL (don't forget peripheral iridotomy)
- Miochol to bring pupil down. use prior to AC IOL or after sulcus IOL is placed.

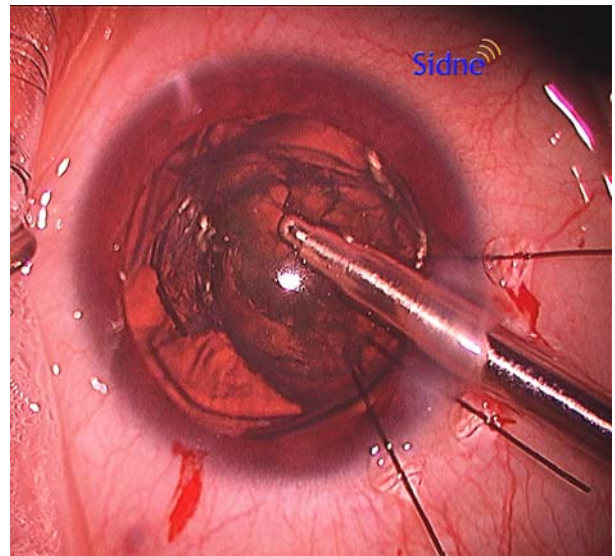
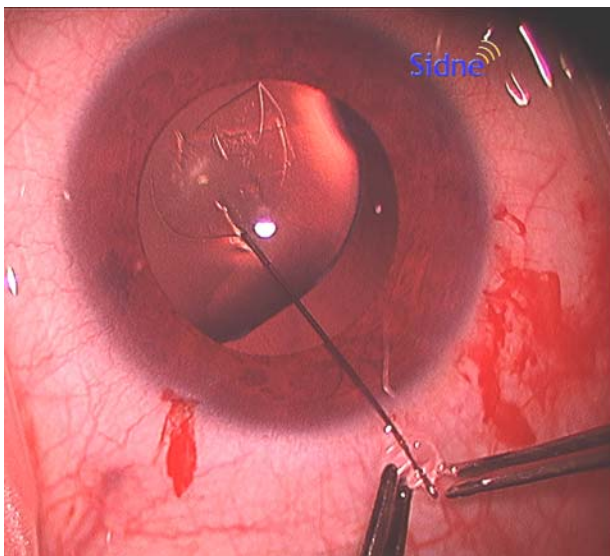
### **Sequestered phacoemulsification for early vitreous loss**

- If topical do subtenons injection. incise conjunctiva in a quadrant and dissect posterior to the equator and place 2 cc non preserved lidocaine behind the eye
- Use only viscous dispersive viscoelastic (eg Viscoat) from this point forward as it causes less ocular hypertension and sticks to other structures.
- Use viscoelastic to lift lens material into the anterior chamber.
- If the material heads south don't chase it and leave it for the vitreous surgeons.
- Try to wedge the residual lens material into a safe position anterior to the iris and away from the posterior capsular tear.
- Make separate 1.5 mm incision for anterior vitrectomy

- Separate irrigation (through paracentesis) and asp/cutter (through larger paracentesis)
- May need to suture original wound to keep chamber formed
- Irrigate away from the sequestered material and cut/suck in the area of the posterior tear/hole.
- Try to get some of the residual cortical material with the anterior vitrector or with removal of residual cortical material with syringe on 27 gauge cannula or 23 gauge visitec canula with viscoelastic to support chamber (dry technique)
- Consider staining with kenalog (see below)
- Replace viscoelastic often to keep residual material sequestered
- Consider placing a 3 piece IOL in the anterior chamber or sulcus and below the residual material as a scaffold for residual material to prevent the material from dropping posterior<sup>5</sup>
- Now with anterior chamber free of vitreous and lens material sequestered from tear with IOL scaphold or viscoelastic use slow motion phaco to remove (low bottle height, low vacuum).
- If pieces are small you can use the Malyugin ring inserted to grab nuclear bits (Neuzil technique)

### Vitreous presenting early due to zonulopathy

- If topical consider subtenons injection. Incise conjunctiva in a quadrant and dissect posteriorly to the equator and place 2 cc non preserved lidocaine behind the eye
- Use triamcinolone stain to identify vitreous and area of weak zonules (see below)
- Trim with anterior vitrector under viscoelastic with anterior approach or consider pars plana approach (if comfortable with this technique)
- Sideways Arshinoff shell to force dispersive viscoelastic into area of weak zonules. first place dispersive in area of weak zonules. then place cohesive across from weak area forcing dispersive into area of weak zonules sealing it off.
- Perform CCC if not already done
- Use cohesive viscodissection between capsule and the cortical material to allow space for CTR or CTS
- Place CTR with lead eyelet of the ring heading out of inserter toward the area of weak zonules to minimize stress of insertion.
- Use hooks or a sutured CTS to support the CTR if needed during the rest of the case



## **Vitreous Presenting mid case – while removing cortical material.**

This seems to be the most common time for vitreous loss. Often one will get the posterior capsule just as the last nuclear fragment is taken. Of course there is no reason to convert to ECCE in this case. The following steps are useful<sup>1</sup>

### **Posterior Capsule damage noted while removing cortical material**

- Place viscoat in area of tear or dialysis before removing instruments
- Make separate 1.5 mm incision for anterior vitrectomy
- Separate irrigation (through paracentesis) and asp/cutter (through larger paracentesis)
- May need to suture original wound to keep chamber formed
- Irrigate high and cut/suck low – creates a pressure gradient to push the V back
- Settings low vacuum 100 range, low bottle height 50 range, max cut rate
- Try to get some of the residual cortical material
- Dry removal of residual cortical material with syringe on 27 gauge cannula or 23 gauge vitrector cannula
- Use J-cannula or paracentesis if needed for subincisional material
- Consider staining with kenalog (see below)
- Place IOL if possible in sulcus (adjust power) or use an AC IOL (don't forget peripheral iridotomy)
- Miochol to bring pupil down. use prior to AC IOL or after sulcus IOL is placed.

### **Zonular defect while removing cortical material**

- Place viscoat in area of weak zonules before removing instruments
- Make separate 1 or 1.5 mm incision for anterior vitrectomy
- Separate irrigation (through paracentesis) and asp/cutter (through larger paracentesis)
- May need to suture original wound to keep chamber formed
- Irrigate high and cut/suck low – creates a pressure gradient to push the V back
- Consider using iris hooks to support capsule.
- Consider placing CTR after cohesive viscodissection. Henderson CTR is a nice choice in this setting (rings has ripples to ease cortex removal following placement)
- Place a 3 piece IOL with haptics toward weak area if small defect; place CTR if less than 4 clock hours; or place sutured CTS if 4-7 clock hours.
- Miochol to bring pupil down

## **Vitreous Presenting late in the case – while placing IOL**

This is the least problematic and least common time to lose vitreous. The main issue is to make sure the IOL is stable while attending to the vitreous and then to secure a proper IOL in either the AC, sulcus, or bag<sup>1</sup>. The strategy will depend on whether the vitreous is presenting through a later tear or zonular weakness (more common)

### **Posterior capsular tear with late vitreous loss**

- Place viscoat in area of tear before removing instruments
- Make separate 1 or 1.5 mm incision for anterior vitrectomy

- Separate irrigation (through paracentesis) and asp/cutter (through larger paracentesis)
- May need to suture original wound to keep chamber formed
- Irrigate high and cut/suck low – creates a pressure gradient to push the V back
- Settings low vacuum 100 range, low bottle height 50 range, max cut rate
- If the sulcus can support an IOL, then
  - Move existing 3 piece IOL into sulcus
  - Can replace existing single piece acrylic (SPA) IOL with 3 piece for sulcus as you should not place SPA in the sulcus<sup>7</sup>.
  - Consider reverse optic capture (ROC) of SPA optic if CCC is round and centered by pulling SPA anterior captured by CCC<sup>8</sup>.
  - With 3 piece IOL in sulcus and round and centered CCC best course is to can displace optic posteriorly which seals off anterior chamber
- If the tear in the posterior capsule is round and secure consider placing IOL in bag
  - Place viscoat in hole
  - Gently place IOL into the bag (usually SPA is more controlled)
- Miochol to bring pupil down

### **Zonular defect with late vitreous loss**

- Place viscoat in area of weak zonules before removing instruments
- Make separate 1 or 1.5 mm incision for anterior vitrectomy
- Separate irrigation (through paracentesis) and asp/cutter (through larger paracentesis)
- May need to suture original wound to keep chamber formed
- Irrigate high and cut/suck low – creates a pressure gradient to push the V back
- Settings low vacuum 100 range, low bottle height 50 range, max cut rate
- Place a 3 piece IOL with haptics toward weak area if small defect; place CTR if less than 4 clock hours; or place sutured CTS if 4-7 clock hours.
- Miochol to bring pupil down

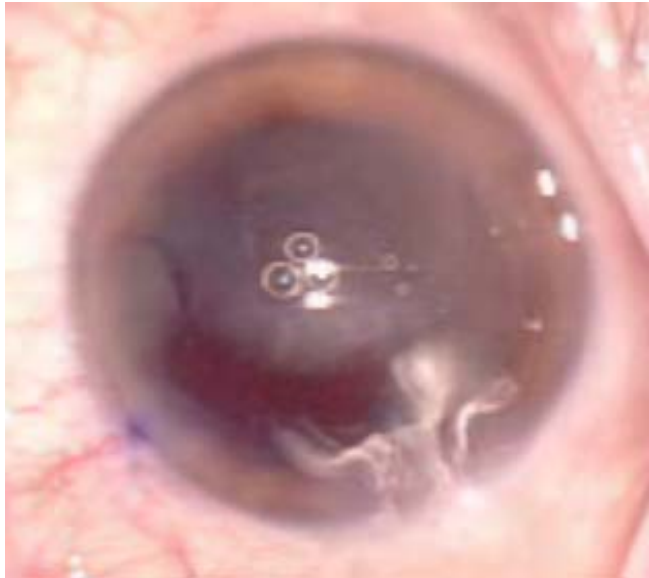### **Staining the Vitreous with triamcinolone**

Scott Burk at Cincinatti Eye described using triamcinolone (not approved by the FDA for this indication) to stain vitreous to better visualize vitreous prolapsed into the anterior chamber<sup>4</sup>. As triamcinolone is not approved by the FDA for this indication and as some retinal surgeons have had sterile and even infectious endophthalmitis with triamcinolone injection its use is controversial. However, I find it to be a very useful adjunct to anterior vitrectomy. You can simply dilute the nonpreserved triamcinolone (FDA approved for posterior segment inflammation) 10:1 (eg Triesence)

An alternative to the more expensive non preserved triamcinolone is to wash the preservative off the triamcinolone using a filter as described by Burk and then dilute 10:1 as described below:

- TB syringe to withdraw 0.2 ml of well shaken triamcinolone 40mg/ml
- Remove the needle and replace with a 5 (or 22) micron syringe filter (eg Sherwood Medical)
- depress the syringe so the large triamcinolone molecules will be stopped by the filter while the preservative and solvent will pass through the filter.
- The triamcinolone will be trapped on the syringe side of the filter
- Transfer the filter to a 5 ml syringe filled with balanced salt solution (BSS)

- Gently force the BSS through the filter to further rinse off preservative
- Repeat rinsing a few times
- Place a 22 gauge needle on the distal end of the filter
- Draw 2 ml of BSS into the syringe through the filter to resuspend the Kenalog
- The Kenalog (now without preservative and dilute 10:1) will stain vitreous white



## References

1. Oetting, TA, *Cataract Surgery for Greenhorns*, Available at <http://cataractsurgeryforgreenhorns.blogspot.com/2009/07/anterior-vitrectomy.html> , accessed 8/17/2010.
2. Arbisser LB, Charles S, Howcroft M, Werner L, Management of vitreous loss and dropped nucleus during cataract surgery, *Ophthalmol Clin North Am.* 2006 Dec;19(4):495-506.
3. Henderson BA, *Essentials of Cataract Surgery*, Slack Inc, Thorofare NJ, 2007
4. Burk SE, Da Mata AP, Snyder ME, Schneider S, Osher RH, Cionni RJ. Visualizing vitreous using Kenalog suspension *J Cataract Refract Surg.* 2003 Apr;29(4):645-51
5. Kumar DA, Agarwal A, Prakash G, Jacob S, Agarwal A, Sivagnanam S, IOL scaffold technique for posterior capsule rupture, *J Refract Surg.* 2012 May;28(5):314-5
6. Osher RH, Slow motion phacoemulsification approach, *J Cataract Refract Surg.* 1993 Sep;19(5):667.
7. Chang DF, Masket S, Miller KM, Braga-Mele R, Little BC, Mamalis N, Oetting TA, Packer M; ASCRS Cataract Clinical Committee, Complications of sulcus placement of single-piece acrylic intraocular lenses: recommendations for backup IOL implantation following posterior capsule rupture, *J Cataract Refract Surg.* 2009 Aug;35(8):1445-58.
8. Jones JJ, Oetting TA, Rogers GM, Jin GJ, Reverse Optic Capture of the Single-Piece Acrylic Intraocular Lens in Eyes With Posterior Capsule Rupture, *Ophthalmic Surg Lasers Imaging.* 2012 Sep 6:1-9

## Conversion to ECCE

Conversion to ECCE often comes at a difficult time. The lens is about to fall south, the vitreous has prolapsed and the surgeon is stressed. Understanding the steps and process of conversion to ECCE is essential and study before the crisis will help soothe the stress when this inevitable process occurs. We will cover several areas: identifying patients at risk for the need for conversion to ECCE, indications for conversion, conversion from topical to sub-tenon's, wound preparation, expressing the lens material, closure of the wound, placement of the IOL, post operative issues and a brief section on anterior vitrectomy.

### Patients at risk for conversion to ECCE

One of the most important parts of the pre-operative process for cataract patients is to assess the difficulty factors (see section on difficulty factors) that may lead to conversion to ECCE or otherwise complicate the procedure. You may want to add operative time to your schedule or ask for additional equipment. You may want to change to a superior limbal wound which facilitates conversion to an ECCE rather than a temporal clear corneal incision. You may want to do a retrobulbar block rather than topical anesthesia as the case may last longer or is more likely to become complicated. Or you may want someone more experienced to do the case.

### Difficulty Factors<sup>1</sup> (in decreasing order of importance):

- Zonular Laxity (PXF, h/o trauma, marfan's ...)
- Rock Hard Lens (red or black lens)
- Pupil size (why is it small? PXF, DM s/p laser, CPS, floppy from Flomax)
- Cannot lay flat for very long, eg. COPD, claustrophobia, tremor, severe obesity
- Big brow limiting superior access
- Narrow angle limiting AC space
- Predisposition to corneal decompensation: e.g. guttata, PPMD, hard nucleus
- Poor red reflex white/black cataract making CCC difficult
- Past surgery such as existing trab or past PPVx
- Predisposition to exposure: eg: botox, past lid trauma, DM
- Anticoagulants e.g., coumadin, ASA
- Monocular

### Indications for conversion

Conversion to ECCE is indicated when phacoemulsification is failing. Sometimes this is due to a very hard lens which does not submit to ultrasound or a lens that is hard enough that the surgeon is concerned that the required ultrasound energy will harm a tentative cornea, e.g. Fuchs' endothelial dystrophy or posterior polymorphous dystrophy (PPMD). Sometimes one will convert to ECCE when an errant capsulorhexis goes radial especially with a hard crystalline lens when the surgeon is concerned that the risk of dropping the lens is too great with continued phacoemulsification. Rarely now with Trypan Blue dye, a surgeon will choose to convert to ECCE when the anterior capsule is hard to see and capsulorhexis must be completed with the can opener technique. More often the conversion is indicated when the crystalline lens is loose from weak zonules or a posterior capsule tear which make phacoemulsification less safe than extending the wound and removing the residual lens material. Indications for conversion to ECCE include:

- Hard crystalline lens or unstable endothelium
- Radial tear in anterior capsule with hard lens
- Poor visualization despite Trypan dye
- Posterior capsular tear
- Zonular dialysis

### Converting to subtenon's anesthesia.

Often we convert cases from topical clear corneal to ECCE. While the ECCE can be done under topical it is usually more comfortable and safer to give additional anesthetic which is typically a sub tenon's injection of bupivacaine and lidocaine. This will provide some akinesia and additional anesthesia. There is usually subconjunctival hemorrhage and if the injection is made too anterior it can cause chemoisis and ballooning of the conjunctiva. The steps of the sub tenon's injection are outlined in the anesthesia section above.

### Converting the Wound

The major step toward converting to ECCE is to either extend the existing wound or close and make another. The ECCE will require a large incision of from 9-12 mm which is closed with suture. The decision to extend the existing wound or make a new wound hinges on several factors: location of the original wound, size of the brow, past surgical history, and possible need for future surgery.

Original wound	Advantages of making new wound for ECCE	Advantages of extending wound for ECCE
<b>Temporal</b>	Allows limbal incision superior Allows lids to cover suture Should iris damage occur it will be superior Simple to start fresh	Protects existing trab Avoids big brow
<b>Sup Temporal Left eye</b>	none	Already have sup incision No need to change position
<b>Inf Temporal Right Eye</b>	Allows limbal incision superior Allows lids to cover suture Should iris damage occur it will be superior Simple to start fresh	Protects existing trab Avoids big brow
<b>Superior</b>	none	Already have sup incision No need to change position

**Making a new incision** during conversion is identical to that for a planned ECCE. The original incision is closed with a 10-O nylon suture. The surgeon and microscope are rotated as the surgeon should sit superior. The steps to make a new superior incision are:

- Conjunctival peritomy of about 170 degrees

- Use 64 or crescent blade to make limbal groove with a chord length of 11mm
- Bipolar cautery for hemostasis
- Use keratome to make initial incision starting in groove into AC
- Extend initial incision to full length of groove (with scissors or knife)
- Safety sutures are preplaced usually 7-O vicryl

**Extending an existing incision** can be tricky and the technique is different for scleral tunnels compared to clear corneal incisions. However in both cases the original extension is brought to the limbus. In the case of an original scleral incision the incision is brought anterior to join the limbus on either end before extending along the limbus for a chord length of about 11mm. In the case of an existing corneal incision the corneal incision is brought posterior toward the limbus before extending the wound along the limbus for a chord length of about 11mm. When iris hooks are being used in a diamond configuration the wound can be extended to preserve the sub-incisional hook and the large pupil<sup>2</sup>.

- Conjunctival peritomy of about 170 degrees
- Use 64 or crescent blade on either side of the existing wound to make a limbal groove with a chord length of 11mm
- Bipolar cautery for hemostasis
- Use Crescent to bring existing scleral wound anterior or existing corneal wound posterior to join limbus
- Extend initial incision to full length of groove (with scissors or knife)
- Safety sutures are preplaced usually 7-O vicryl

## Removing the lens

One has to be far more careful when removing the nucleus during the typical conversion to ECCE which comes along with vitreous loss. First the anterior capsule must be large enough to allow the nucleus to express which may require relaxing incisions in some cases. When the zonules are weak or the posterior capsule is torn the lens cannot be expressed with fluid or external pressure as is often done with a planned ECCE with intact capsule/zonules. After any vitreous is removed (see below), the lens must be carefully looped out of the anterior chamber with minimal pressure on the globe. If the posterior capsule and zonules are intact then the lens can be expressed as described with a planned ECCE.

### Removing Lens with intact capsule complex

- mobilize lens (physically with cystitome or with hydrodissection--be careful)
- Lens removed w/ lens loop or w/ counter pressure technique
- Wound is closed with safety sutures and additional central vicryl suture
- Cortical material is removed using I/A device (either automated or manual)
- Instill ophthalmic viscoelastic device (OVD)
- Lens is placed in the posterior chamber
- Wound is closed with 10-O nylon and vicryl sutures are removed.
- OVD is removed

### Removing Lens with vitreous present

- mobilize lens with viscoat canulla -- tip lens so that wound side is anterior)



- slip lens loop under lens, toe up, remove lens
- Wound is closed with safety sutures and additional central vicryl suture
- Anterior vitrectomy (see below)
- Cortical material is removed using dry technique or anterior vitrector
- instill ophthalmic viscoelastic device (OVD)
- Lens is placed in the sulcus or in the anterior chamber
- Wound is closed with 10-0 nylon and vicryl sutures are removed
- OVD is removed

**Placement of the IOL** IOL selection with ECCE conversion depends on the residual capsular complex<sup>3,4</sup>. The key to IOL centration is to get both of the haptics in the same place: either both in the bag or both in the sulcus.

- When the posterior capsule is intact following a conversion to ECCE the anterior capsular opening is usually poorly defined which can make bag placement difficult. If the anterior capsule and thus the bag is well defined, then place a single piece acrylic IOL without folding it directly and gently into the bag using kelman forceps.
- When the posterior capsule is intact and the anterior capsule is poorly defined then place a 3 piece IOL in the sulcus such as a large silicone IOL or the MA50 acrylic by placing these directly and unfolded into the sulcus with kelman forceps. Make sure that both haptics are in the sulcus.
- When the posterior capsule is damaged, if enough anterior capsule and posterior capsule is left to support the IOL, define the sulcus with viscoat and place the IOL directly in the sulcus. Make sure both haptics are in the sulcus. If the IOL does not seem stable then place McCannel sutures to secure the IOL to the iris or remove and replace with an AC IOL (don't forget to place a PI with vitrector).
- When the capsule is severely damaged and cannot support an IOL then place the IOL in the anterior chamber. Use kelman forceps to place the IOL, then secure the chamber, and use ainsky hook to place the AC IOL into its final position. (don't forget to place a PI with vitrector).

## **Post operative issues.**

Postoperative care for patients following conversion from phaco to ECCE is a bit more complicated and focuses on preventing cystoid macular edema and limiting induced astigmatism. Often the care is very similar to that of a planned ECCE with about 3 post operative visits one the same day or next, one a week later, and one about 5-6 weeks later. Depending on the amount of astigmatism the patient may require several visits to sequentially remove sutures while eliminating induced astigmatism.

### **First post operative visit**

Often on the same afternoon 4-6 hours following surgery or next morning with the primary emphasis to check the IOP, look for wound leaks and scan for residual lens material or vitreous in the anterior chamber. Most wound leaks should be sutured but if the AC is not formed closing these is mandatory. Residual nuclear material should be removed in the next few days if present but residual cortical material will often dissolve away with little inflammation. You would expect poor vision in the 20/200 range due to astigmatism and edema. The anterior chamber should be formed and typically has moderate cell (10-20 cells/hpf with 0.2 mm beam). If the IOP is less than 10 search hard for a leak using Siedel testing. If the IOP is in the 10-29 range all is probably OK

unless the patient is a vasculopath and then the upper limit of IOP tolerance should be lowered. If the IOP is in the 30-39 range consider aqueous suppression. If the IOP is >40 than consider aqueous suppression and bleeding down the IOP with the paracentesis or anterior chamber tap. The IOP should be rechecked 60-90 minutes later to ensure success with your treatment. Look at the fundus and rule out retinal detachment and choroidal effusion or hemorrhage. Typically patients are placed on prednisolone acetate 1% i drop 4 times a day, cyclogyl 1% i drop 2 times a day, and an antibiotic i drop 4 times a day for the next week.

### **Week 1 post operative visit**

The vision and pressure should dramatically improve in patients over the next week where you have converted to ECCE. The vision should be in the 20/100 range with an improvement with pin hole to 20/50. The vision is usually limited by residual edema and astigmatism. In a study of our ECCE we found about 7 diopters of cylinder at the one week visit. You should expect very little inflammation and document that no RD exists. Search for residual lens material in the anterior segment and posterior pole. You can discontinue the cyclogyl and the antibiotic. Slowly taper the prednisolone acetate like i gtt qid for 7 more days, then i gtt tid for 7 days, then gtt bid for 7 days, then i gtt qd for 7 days, then discontinue. If the patient is at risk for CME (eg vitreous loss) than keep on prednisolone qid and start a non steroidal like acular I gtt qid until the next visit 4 -6 weeks later.

### **Week 5 post operative visit**

The vision should continue to improve as the astigmatism settles and the cornea clears further. The eye should be comfortable. The vision should be in the 20/80 range with an improvement to 20/40 with pin hole. In our study the astigmatism induced by ECCE sutures was about 5.0 diopters at the incision. The anterior segment should be quiet and the IOP normal (unless the patient is a steroid responder). Consider CME as a possibility in patients where conversion was required as these cases are often long and can involve vitreous loss with OCT, FFA, or clinical exam.

But the main issue is astigmatic control with suture removal. Use keratometry, refraction, streak retinoscopy, or topography to guide in suture removal. If the keratometry is 45.00 at 90, and 40.00 at 180 then look for tight sutures at around 90 degrees (12 oclock) that are causing 5 diopters of cylinder. You can take only one suture at 5 weeks, then can take maybe 2 at a time by 8 weeks. The plan is to remove a suture and see how the cornea settles. When the astigmatism is less than about 1.0 to 1.5 diopters you should stop. Use antibiotic drops for a few days after suture removal. After this visit you should consider the following choices with each visit (don't waste too much time thinking about other possibilities and remember not everybody is going to be 20/20.

:

1. pull a stitch (i.e. cyl at axis of stitch is greater than 1 on MR)
2. give glasses (i.e. no stitch to pull or cylinder is less than 1 on MR)
3. get FFA or OCT because you suspect CME

### **References**

- 1) Chang DF, Oetting TA, Kim T, *Curbside Consultations in Anterior Segment Surgery*, Slack Inc, Thorofare NJ, 2007
- 2) Henderson BA, *Essentials of Cataract Surgery*, Slack Inc, Thorofare NJ, 2007

# Approaching Different Kinds of Cataract

## Ectopia lentis

Displacement of the lens

- Subluxed – partially displaced within pupillary aperture
- Luxated or completely displaced from the pupil congenital, developmental, or acquired

Epidemiology

- Traumatic most common
- Greater than 50% of patients with Marfan's syndrome exhibit ectopia lentis

Pertinent clinical features

- Sub or total luxation of the lens
- Phacodonesis
- Marked lenticular astigmatism
- Iridodonesis
- Impaired accommodation

Non-traumatic differential diagnosis

1) Primarily ocular

- Pseudoexfoliation
- Simple ectopia lentis
- Ectopia lentis et pupillae
- Aniridia
- Congenital glaucoma

2) Systemic

- Marfan's syndrome
- Homocystinuria
- Weil-Marchesani syndrome
- Hyperlyseemia
- Ehlers Danlos
- Sulfite oxidase deficiency

Surgical therapy options

- ICCE
- Phaco/ECCE
  - 1) Attend to any vitreous in anterior chamber – staining with Kenalog
  - 2) Iris hook stabilization of capsular
  - 3) Capsular tension ring with or without cionni modification
  - 4) IOL in bag – mild cases of aided by CTR/cionni ring or CTS
  - 5) Iris fixated posterior or anterior IOL
  - 6) Angle supported IOL
  - 7) sulcus sutured posterior chamber IOL
  - 8) Contact lens or spectacles

## Intumescent cortical cataract

### Etiology

- Opacification of the cortical lens fibers
- Swelling of the lens material creates intumescent cataract

### Clinical features

- Initially vacuoles and water left in the lens cortex
- Wedge shaped opacities or cortical spokes
- Progresses to form white intumescent cortical cataract
- Risk of phacolytic glaucoma

### Risk factors

- Smoking
- Ultraviolet light exposure
- Diabetes mellitus
- Poor nutrition
- Trauma

### Phaco/ECCE

- Capsular staining techniques
- Capsulorhexis techniques
  - Initial small tear
  - Removal of liquid cortical material to relieve capsular tension
  - Liberal use of viscoelastic material

### Complications of surgery

- Increased risk of capsular radial tear
- Increased risk of vitreous loss
- Increased risk of loss of lens material into vitreous

## Hypermature cataract

### Etiology

- Opacification of the cortical lens fibers
- Swelling of the lens material creates intumescent cataract
- Degenerated cortical material leaks through capsule leaving wrinkled capsule

### Pertinent clinical features

- Wrinkled anterior capsule
- Increased anterior chamber flare
- Calcium deposits in lens
- White cortical material
- Risk of phacolytic glaucoma

### Phaco/ECCE

- Capsular staining with Trypan Blue
- Capsulorhexis techniques
  - Initial small tear

- Removal of liquid cortical material
- Use of viscoelastic material in anterior chamber and bag

#### Complications of surgery

- Increased risk of capsular radial tear
- Increased risk of vitreous loss
- Increased risk of zonular dialysis
- Increased risk of loss of lens into the vitreous

### **Morgagnian cataract**

#### Etiology

- Opacification of the cortical lens fibers
- Can be swelling of the lens material as in intumescent cataract
- Can be wrinkled capsule as in hypermature cataract
- Hallmark – liquified cortex allows nucleus to move freely in bag

#### Pertinent clinical features

- Wrinkled anterior capsule
- Increased anterior chamber flare
- Dense brown nucleus freely moving in capsular bag
- Calcium deposits within the lens

#### Phaco/ECCE

- Capsular staining techniques
- Capsulorhexis techniques
  - Initial small tear
  - Removal of liquid cortical material
  - Use of viscoelastics material in anterior chamber and bag
- Stabilize nucleus with viscoelastic

#### Complications of surgery

- Increased risk of capsular radial tear
- Increased risk of vitreous loss
- Increased risk of zonular dialysis
- Increased risk of loss of lens into the vitreous

### **Anterior polar cataracts**

#### Etiology

- Opacity of the anterior subcapsular cortex and capsular
- Bilateral
- Non progressive usually
- Frequently autosomal dominant

#### Clinical features

- Usually asymptomatic – good vision
- Central opacity involving the anterior capsular
- Associated with microphthalmos, persistent papillary membrane, anterior lentic

- Differential diagnosis includes penetrating capsule trauma

Phaco/ECCE – w/capsulorhexis start away from polar cataract make bigger and go around polar cataract if possible

## Posterior polar cataracts

### Etiology

- Opacity of the posterior capsular cortex and capsule
- Familial autosomal dominant bilateral; sporadic unilateral
- Slowly progressive

### Pertinent clinical features

- Good vision but at nodal point more symptomatic than anterior polar
- Central opacity involving the posterior capsule
- Glare
- Differential diagnosis includes
  - Posterior subcapsular cataract
  - Penetrating capsule trauma
  - Mittendorf dot

### Phaco/ECCE

- No hydrodissection
- Sculpt out a bowl to relieve capsular tension or use the V groove technique
- Gentle hydrodelineation and slow careful visco dissection
- Leave central opacity or take at the end of surgery

### Complications

- Increased risk of posterior capsular tear
- Increased risk of vitreous loss
- Increased risk of loss of lens material into vitreous

## Perforating and penetrating injury of the lens

### Etiology of this disease

- Penetrating injury results in cortical opacification at site
- Rarely can seal resulting in a focal opacity
- Usually progresses to complete opacification

### Pertinent clinical features

- Focal cortical cataract
- White cataract with capsular irregularity/scar
- Full thickness corneal scar

### Laboratory testing

- B-scan ultrasound – posterior capsular intact? Intraocular foreign body?
- CT scan to rule out intraocular foreign body

## Phaco/ECCE

- Capsular staining to identify traumatic tear
- Treat similar to posterior Polar cataract
  - No hydrodissection if posterior penetration suspected
  - Consider use of viscodissection and hydrodelineation
- Usually can aspirate in younger patients without need for nucleofractis

## Complications

- Increased risk of anterior radial capsular tear
- Increased risk of vitreous loss
- Increased risk of lens material in vitreous
- Increased risk of retinal detachment

## Diabetes mellitus and cataract formation

### Etiology

- Increased aqueous glucose concentration drives glucose into lens
- Glucose converted into sorbitol that is not metabolized by lens
- Sorbitol creates an osmolar gradient forcing hydration of the lens
- This sorbitol induced lenticular hydration
  - Decreases accommodation
  - Changes the refractive power of the lens
  - Generates cataract

### Pertinent clinical features

- Snowflake or true diabetic cataract
  - Bilateral
  - Posterior and anterior subcapsular, cortical vacuoles and clefts
- Typical nuclear, cortical, or posterior subcapsular cataracts

### Phaco/ECCE

- Indicated when view of posterior pole is poor
- Standard technique
- consider monofocal acrylic IOL with any retinopathy

### Complications

- Exacerbation of diabetic macular edema
  - Focal or grid laser therapy prior to surgery if indicated/possible
  - anti VEGF agents commonly used prior to surgery
  - Sutured wound to allow early laser therapy if indicated
- Increased risk of cystoid macular edema
  - Pretreatment with steroid and non-steroidal drops
  - Prophylactic treatment for 1-3 months with steroid and/or non-steroidal drops
- Can present with rapid white cataract under tension
  - will need Trypan blue (or ICG but this is not approved by the US FDA)
  - be careful with initial capsule tear as it is prone to go radial (Argentinean flag sing)
  - make an initial tear, remove anterior cortical material, then add more OVD
  - consider very viscous OVD like Healon 5 or Healon GV

## Cataract associated with uveitis

### Etiology

- Posterior subcapsular cataract
  - Initially an iridescent sheen appears in the posterior cortex
  - Followed by granular and plaque like opacities
- May progress to or involve anterior subcapsular cortical fibres
- May present as cortical cataract without posterior subcapsular component
- Associated with uveitis and corticosteroids to treat uveitis
- May progress rapidly to a mature cataract

### Pertinent clinical features

- Central opacity of the posterior cortical fibers
- Cortical cataract
- Posterior synechiae
- Papillary membrane
- Anterior chamber cell or flare

### Prior to phaco/ECCE

- Several months without inflammation
- 1 week prior to surgery suppresses immune system
  - Topical agents in those patients who typically quiet with topical agents alone
  - Oral prednisone in those that typically require oral steroid with a flare
  - Consider intraoperative IV steroids

### Phaco/ECCE

- Synechiolysis with viscoelastic agents/hooks
- May require iris hooks to stabilize floppy iris and control papillary aperture
- Capsular dye to allow continuous tear
- IOL material acrylic=heparin coated pmma better than silicon
- Consider aphakia in children with JRA

### Complications of cataract surgery

- Increased risk of post operative inflammation
- Increased risk of post operative pressure spike
- Increased risk of cystoid macular edema
- Consider using steroid and non-steroidal drops for months following surgery

## Exfoliation syndrome (pseudoexfoliation)

### Etiology

- Systemic disease in which a fibrillar material is deposited in the eye
  - Similar material to the basement membrane proteoglycan
  - The material is found throughout the body
- Within the eye the fibrillar material comes from the lens capsule, iris, and ciliary body
- The zonules are weak in this condition
- Often asymmetric or even unilateral
- Glaucoma develops when the fibrillar material blocks the trabecular meshwork



## Epidemiology

- Patients tend to be over 60 years of age
- Geographic clustering suggests a hereditary pattern
  - In Scandinavia for example pseudoexfoliation causes 75% of glaucoma
- Glaucoma develops in 22-82% of patients with exfoliative material
- Increased incidence of age related cataract

## Pertinent clinical features

- Ground glass appearing deposition of fibrillar material on anterior lens capsule
  - Iris may sweep material into rings on the lens capsule
  - Best viewed with dilation
- Transillumination defect and fibrillar material at the papillary margin
- Open angle with brown clumps of fibrillar material on trabecular meshwork
- Flakes of fibrillar material on corneal endothelium
- Evidence of zonular weakness
  - Phaco or iridodonesis
  - Lens subluxation or even luxation

## Phaco/ECCE

- Use of iris hooks for capsular support during phacoemulsification
- Use of capsular tension ring with or without Cionni modification
- Placement of AC IOL, sutured Cionni ring with capsular IOL, sutured PC IOL
- Sutured iris IOL
- Consider surgery sooner while zonules are relatively strong
- Minimize zonule stress during surgery

## Complications of phaco/ECCE

- Increased risk of capsular radial tear
- Increased risk of zonular dialysis
- Increased risk of loss of lens material into vitreous
- Increased risk of late dislocation of IOL capsular bag complex into vitreous
- Post operative intra-ocular pressure spike
  - Completely remove OVD
  - Intra-operative miotic and postoperative aqueous suppressant