



EPILEPSY AND SEIZURES

2012-2013 Neurology Clerkship
Ninith Kartha, MD

What are seizures?

- Definition of seizure: “paroxysmal episodes of brain dysfunction manifested by stereotyped alteration in behavior”
- Clinical manifestation depends on region of brain seizing
- Causes: primary CNS dysfunction, metabolic disorder
- Epilepsy: recurrent and unprovoked seizures
- Cellular definition: excessive or oversynchronized discharges of cortical neurons
 - GABA receptor mediates inhibition responsible for normal termination of a seizure
 - NMDA (Glutamate) receptor activation required for propagation of seizure activity

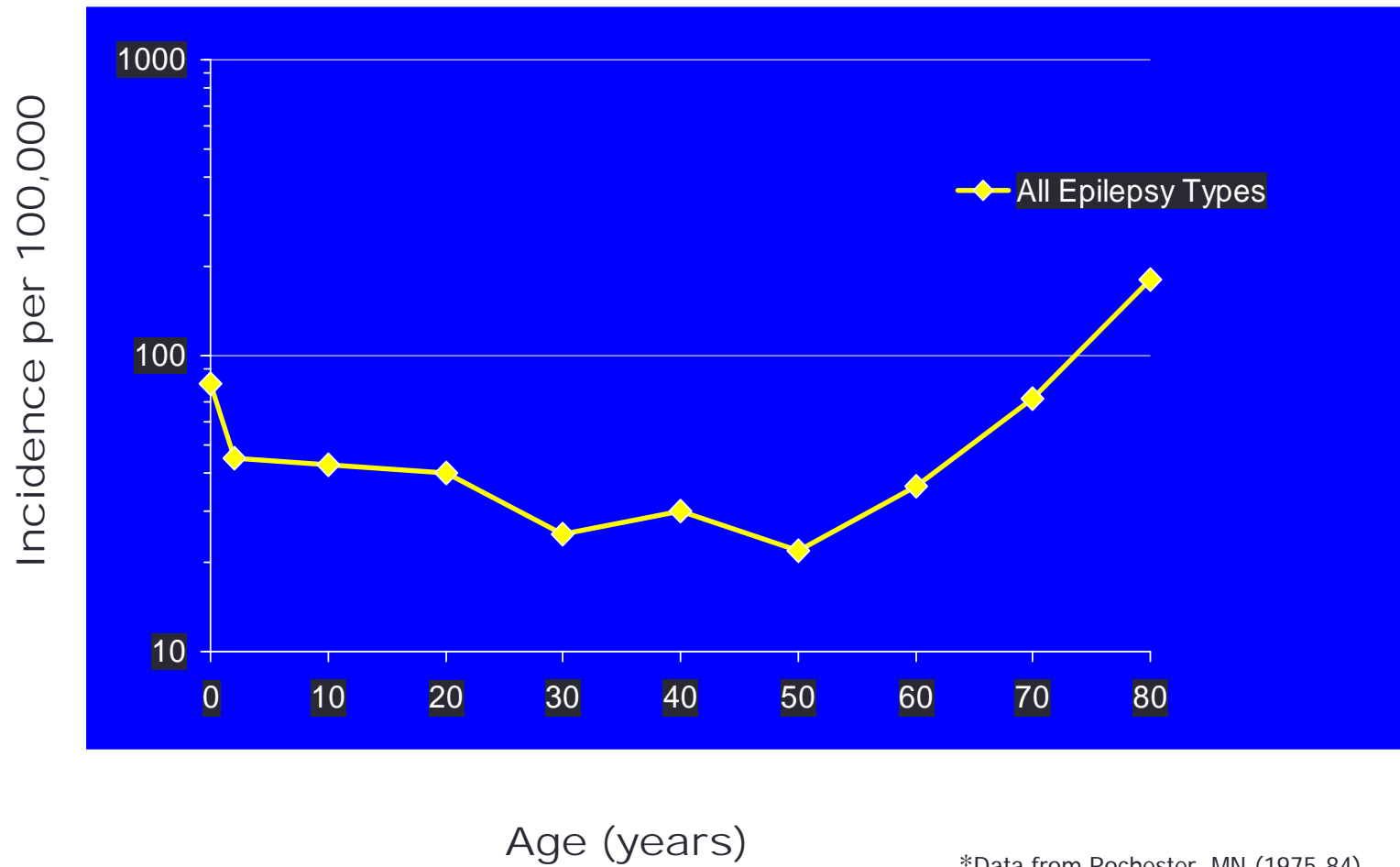


Epidemiology

- Approximately 1% population (3 million epilepsy cases in US).
- Second most common neurological disease
- Comparable prevalence in men vs. women

Begley CE et al. Epilepsia 2000;41:342-351
MMWR Weekly. November 11, 1994/43(44);810-811,817-818
Sander JW. Cur Opin neurol 2003;16:165-170

Epilepsy Incidence Rates by Age*



*Data from Rochester, MN (1975-84)
Hauser WA et al. *Epilepsia*. 1991;32:429-445.

Seizure terms

- Ictal= seizure
- Post-ictal= confusion following seizure
- Aura= abnormal sensation preceding loc
- Automatisms= nonsensical involuntary movements
- Tonic= tonic contraction producing extension and arching
- Clonic= alternating muscle contraction-relaxation
- Complex= consciousness impaired
- Simple= consciousness unimpaired
- Partial= focal region involved
- Generalized= whole brain
- Convulsions= shaking
- Grand mal and petite mal=“street terms” for convulsive and non-convulsive seizure respectively

Etiology

- CNS

- Head trauma
 - Seizure in 1 week of injury not predictive of epilepsy
- Stroke
- Vascular malformations
- Mass (tumor/abscess)
- Meningitis/encephalitis
- Congenital malformations/ cortical dysplasias
- Idiopathic

- Systemic

- Hypo/hyperglycemia
- Hypo/hyponatremia
- Hypocalcemia
- Uremia
- Hepatic encephalopathy
- Hypoxia
- Hyperthermia
- Drug overdose or withdrawal
 - EtOH withdrawal sz occurs within 48h

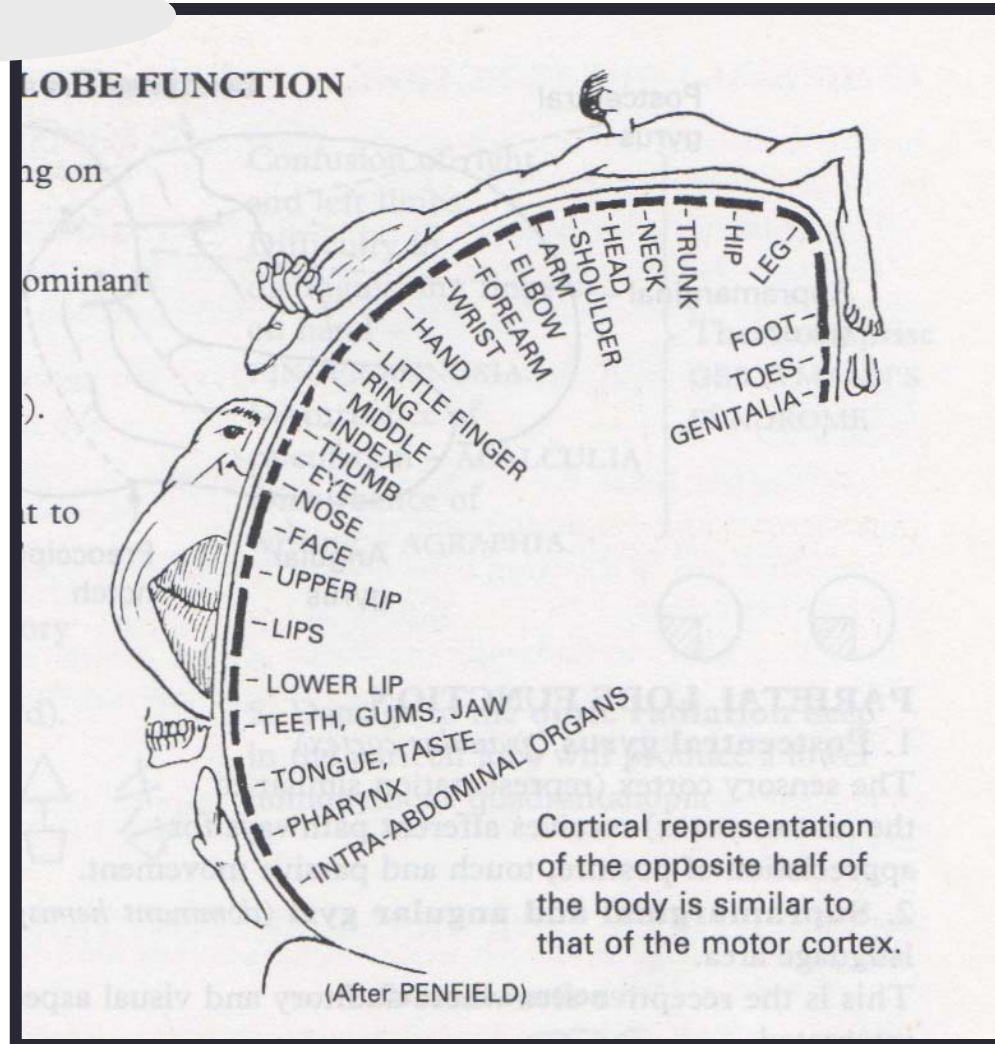
Classification of seizure types

- Partial (focal)
 - Simple partial
 - Motor
 - Somatosensory
 - Autonomic
 - Psychological
 - Complex partial
 - Simple partial with impaired consciousness
 - Partial seizures with secondary generalization
- Generalized
 - Absence
 - Tonic
 - Clonic
 - Tonic-clonic
 - Atonic
 - Myoclonic

Classification

- Partial seizures (focal onset)
 - Simple partial (without impaired consciousness)
 - Motor symptoms (focal motor seizure)
 - Involves motor strip
 - Manifested by abnormal movement of an extremity
 - Jacksonian march- spread to involve contiguous regions
 - Todd's paralysis- post ictal transient hemibody weakness
 - Somatosensory symptoms
 - Involves sensory strip, temporal(hearing and smell) or occipital(visual) lobe
 - Autonomic symptoms
 - Involves temporal lobe (tachycardia, pallor, flushing, sweating)
 - Psychic symptoms
 - Involve frontal or temporal lobe (limbic system): déjà vu, jamais vu, affective disturbances, cognitive deficits, hallucinations

Homunculus



Classification

- Partial seizures
 - Complex partial (impaired consciousness)
 - Typically frontal or temporal lobe onset
 - Often stereotyped for the individual patient
 - Average duration 1-3 minutes
 - Simple partial onset can be followed by impaired consciousness
 - Many times will progress to a generalized seizure
 - Frequently seen in adult onset epilepsy
 - Automatism: coordinated involuntary movements, typically orobuccolingual or nonpurposeful hand movements

Classification of Seizures

- Generalized (diffuse onset)
 - Absence
 - 5-10s LOC w/o loss of postural tone
 - Mild head turn, blinking common
 - Immediate return of awareness
 - Typically resolves by 20y
 - Tonic – arrest of ventilation can cause cyanosis
 - Clonic – without tonic phase
 - Tonic clonic
 - Myoclonic – brief, shock-like contractions, may be localized or generalized
 - Atonic - drop attacks

Classification

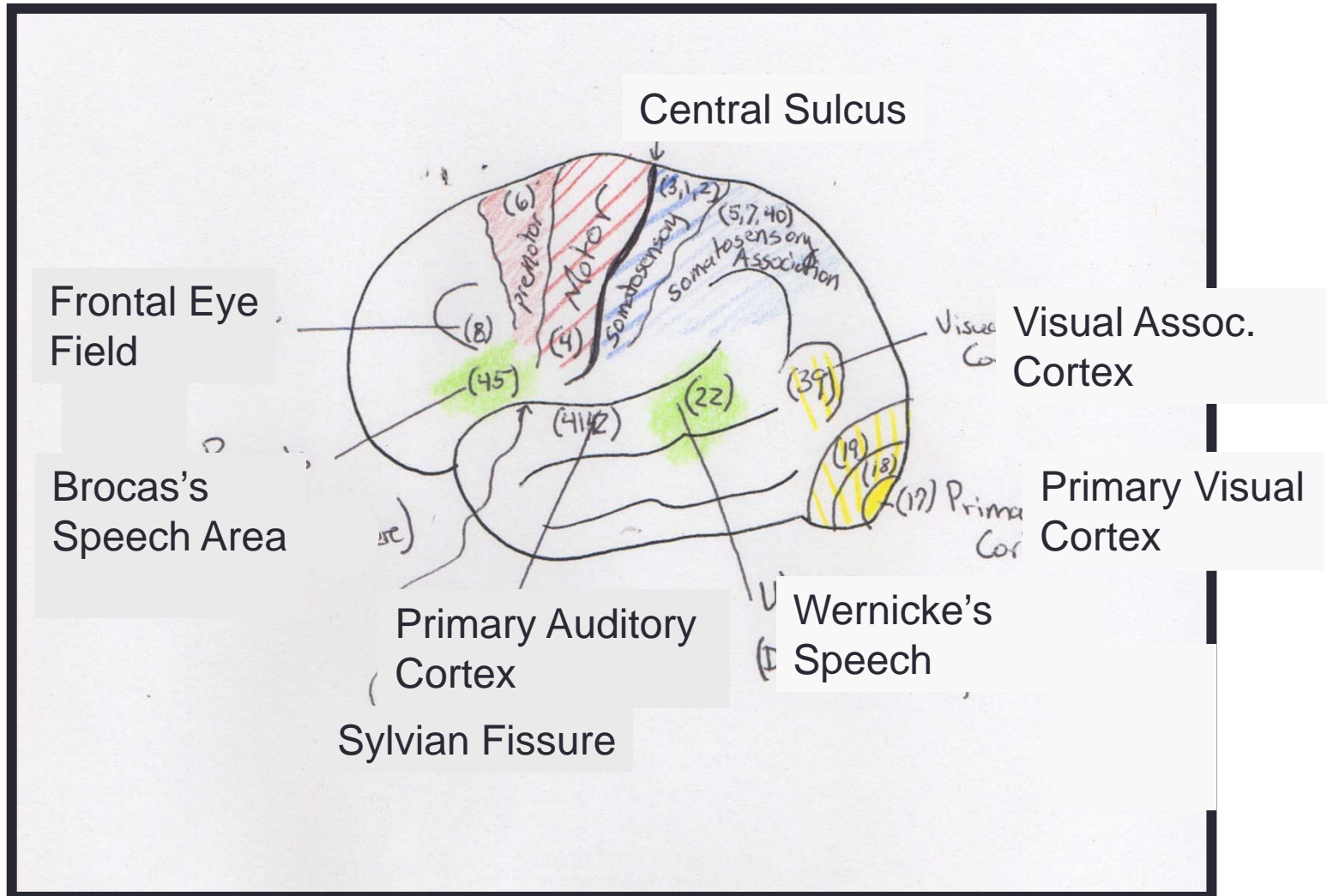
- Pseudoseizures
 - Non-epileptic seizures
 - May be manifestation of conversion disorder, factitious disorder or malingering
 - Features that may distinguish from epileptic seizures
 - Pre-attack preparation, absence of post-ictal confusion
 - “Disorganized” movements, pelvic thrusting, thrashing
 - Bilateral convulsions without loss of consciousness
 - Violent or goal-directed behavior, obscene language,
 - Video EEG may help to diagnose



SEIZURE PHENOTYPES

THINK OF ANATOMY!!

Cortex



Frontal Lobe

- Frontal eye field (Brodman's 8)
 - Lesion: deviation of eyes to ipsilateral side
 - Sz: overstimulation->eyes to contralateral side
- Prefrontal cortex (Brodman's 9-12,46,47)
 - Lesion: deficits in concentration, judgment and behavior
 - Sz: agitation, odd behavior
- Broca's speech area (Brodman's 44,45)
 - Lesion/sz: expressive nonfluent aphasia
- Primary motor cortex (Brodman's 4)
 - Lesion: contralateral hemiparesis, late manifestation spasticity
 - Sz: contralateral twitching, posturing or convulsions

Temporal Lobe

- Hippocampal cortex
 - Bilateral lesions: memory dysfunction
 - Sz: chronic seizures lead to deficits in short term memory
- Wernicke's speech area (Brodmann's 22)
 - Lesion/sz: loss of receptive speech, fluent aphasia
- Anterior temporal lobe
 - Bilateral lesions: Kluver-Bucy syndrome- visual agnosia, hyperorality, hyperphagia, hypersexuality, docility
 - Sz: staring/freezing, oral automatisms
- Primary auditory cortex (Brodmann's 41, 42)
 - Bilateral lesion: cortical deafness
 - Sz: auditory hallucinations
- Olfactory bulb (Brodmann's 34)
 - Lesion: anosmia
 - Sz: olfactory and gustatory hallucinations

Parietal and Occipital Lobes

- Primary sensory cortex (Brodmann's 3,1,2)
 - Lesion: contralateral hemihypestheisa and astereognosis
 - Sz: contralateral sensory symptoms ie tingling, heat
- Occipital lobe (Brodmann's 17)
 - Lesion: contralateral hemianopsia with macular sparing
 - Sz: flashing or colored lights in contralateral visual field



CLINICAL CASES

Case 1

- 38 year old male with episodes of right arm tingling with occasional stiffening of right hand/wrist with no loss of consciousness. Episodes last <30sec can occur multiple times a week.
- PMH:
 - Resected oligodendroglioma involving left parietal cortex 10 years ago.
- Social History:
 - Works as a driver of a snow plow, married no children
- Exam:
 - Within normal limits, non-focal
- EEG:
 - Frequent abnormal discharges and slowing over the left parietal area

Case 1

- Seizure type:
 - Simple partial seizure with onset over the left sensory-motor strip
 - Patient does not lose consciousness=simple
 - Focal onset over left sensory-motor strip=right hand symptoms

Case 2

- 36 year old male with monthly episodes of “burning smell” and epigastric rising and loss of consciousness. Peers noticed “staring spells” with loss of speech and eyes looking to the right. Patient had one episode 2 years ago of convulsions.
- PMH:
 - None
- Social Hx:
 - Works as a paramedic, married with 2 children
- Exam:
 - Within normal limits and non-focal
- EEG:
 - Rare left temporal abnormal discharges

Case 2

- Seizure Type:
 - Complex partial epilepsy with focal onset over the left temporal lobe
 - Patient has aura prior to onset of seizure
 - Aura involves epigastric rising=seen with temporal onset
 - Loss of consciousness=complex partial
 - Loss of speech, aphasia=left hemisphere dominant for speech
 - Eyes look to right=spread of seizure to left frontal eye field

Case 3

- 21 year old female with episodes at night of awakening with bitten tongue. Spouse notices stiffening of arms and legs during sleep. During the daytime, patient is noticed by family to appear agitated with alteration of consciousness.
 - Outside physicians have been concerned for pseudoseizures
- PMH:
 - History of febrile seizures when she was an infant
- Social History:
 - Housewife, has a 3 year old son
- Exam:
 - Within normal limits, non-focal
- EEG:
 - Outpatient 20 minute eeg read as within normal limits
- -> To best characterize these events we recommended VideoEEG
 - >20 seizures recorded in first 24 hrs
 - Episodes of “alteration of consciousness” were seizures.

Case 3

- Seizure Type:
 - Complex partial seizures with onset over the right frontal lobe
 - Alteration of consciousness=complex partial
 - Agitated behavior =frontal/temporal onset

Case 4

- 23 year old female with history of daily episodes of “blurry vision” and right sided tingling lasting “few seconds”. No loss of consciousness
- PMH:
 - None
- Social Hx:
 - College student
- Exam:
 - Post-ictal patient has a right field cut with right arm>leg weakness. Symptoms resolve ~5 minutes after the seizure.
 - Brain MRI-normal
- EEG:
 - Frequent left parietal and occipital abnormal discharges and brief seizures.

Case 4

- Seizure Type:
 - Simple partial seizure with onset over the left parietal/occipital region
 - No loss of consciousness=simple partial seizure
 - Visual symptoms=occipital lobe
 - Right arm>leg tingling=left parietal region
 - Post-ictal symptoms=suggestive of a Todd's paralysis

Case 5

- 22 year old female with history of convulsive seizures that occur around 1 every 3 months. Seizures occur at night and with no warning.
- PMH:
 - None
- Social Hx:
 - College student
- Exam:
 - Within normal limits, non-focal
- EEG:
 - Generalized spike and wave abnormal discharges

Case 5

- Seizure Type:
 - Primary generalized epilepsy with tonic-clonic seizures
 - Loss of consciousness, no aura=generalized onset
 - EEG with generalized discharges=generalized epilepsy



SEIZURE MANAGEMENT

Diagnosis

- Clinical history
- Physical examination: focal deficits, Todd's paralysis
- Diagnostic work-up: pulse ox, glucose, electrolytes, calcium, CBC, renal function, hepatic function, tox screen/EtOH level
- Head imaging: CT/MRI
- LP if fever or meningeal signs present
- EEG confirmation if possible: ictal event or inter-ictal spikes, polyspike discharges, spike-wave complexes

Seizure treatment

- Acute Management
 - 90% of seizures stop without treatment in under 5 minutes
 - Can give lorazepam or diazepam for seizures >5min
 - Monitor ABCDs, avoid injury and aspiration
 - Treat underlying medical conditions
- Long Term Management
 - Decide if therapy needed
 - Sz due to secondary causes (metabolic d/o, EtOH withdrawal, immediately following head trauma/stroke) may not need longterm tx
 - Single generalized tonic-clonic seizure recurs in about 50%
 - Anti-epileptic medications
 - Try single therapy
 - Add second medication if: sz not controlled with single drug and maximal levels/side effects are achieved
 - Treat the seizures, not drug levels

Anti-epileptic medications

- Older Agents

- Phenytoin
- Carbamazepine
- Phenobarbital
- Primidone
- Valproic acid
- Ethosuxamide

- Newer Agents

- Lamotrigine
- Levetiracetam
- Topiramate
- Oxcarbazepine
- Lacosamide
- Zonisamide

Other treatment options

- Ketogenic diet in children
- Surgery
 - Removal of epileptic focus
 - Mostly for patients with temporal lobe seizures
 - Possibility of a 70% chance of cure!!
- VNS (Vagal nerve stimulator)
 - Current given to vagus nerve with theory of decreasing seizures over time

Treatment of the seizing patient

- Ensure airway protection/ position to prevent aspiration
 - Do not place anything in the mouth except when to suction
 - DO NOT try to force suction/airway through clenched teeth
 - When the patient stops convulsing, place patient in lateral decubitus.
 - Begin supplemental oxygen
- Assess safety of patient
 - Ensure lights in room are on
 - Remove any object within reach of patient that could cause injury
 - Loosen clothing
 - Side rails should be up if patient is in bed
 - Do not try to “hold the patient down”
- Obtain vitals including pulse ox, obtain stat accucheck
 - If glucose is < 70 mg/dl (or if accucheck unobtainable) administer amp D50.
 - Note: Ideally, 100mg thiamine IVPB should be given prior to, or soon after, glucose
- Order diagnostic labs: cbc, cmp, mg, phos, tox screens, etoh level, AED levels
- Most seizures cease w/o medical intervention in 1-3 minutes



STATUS EPILEPTICUS

Status epilepticus

- Definition
 - Continuous seizure lasting greater than 30 minutes
 - Two or more sequential seizures without recovery of full consciousness lasting >30 minutes
- Types
 - Generalized convulsive (GCSE)
 - Nonconvulsive status epilepticus (absence, CPS)
 - Simple partial status epilepticus

Status epilepticus

- Lorazepam 0.1 mg/kg IV bolus (4-8 mg), repeat in 5-10 min if needed
- Phenytoin 20 mg/kg IV up to 50 mg/min or fosphenytoin 20 (PE)/kg IV up to 150 mg/min (can be given IM)
 - Additional 5-10 mg/kg of either can be given
- Consider phenobarbital 20 mg/kg or VPA 10-15 mg/kg IV
- If seizure continues: intubation required
- General anesthesia – titrate to burst suppression (continuous EEG monitoring required)
 - Pentobarbital (5 mg/kg load, 0.5-3 mg/kg/hr maint.)
 - Propofol (1-2 mg/kg load over 5 min, 2-10 mg/kg/hr maint.)
 - Midazolam (0.2 mg/kg slow IV bolus, 0.05-0.5 mg/kg/hr maint.)

Status Epilepticus

- Titrate IV agents to burst suppression

